

**North American Society for Pediatric Gastroenterology, Hepatology, and Nutrition
(NASPGHAN) Position Paper on the Diagnosis and Management of Pediatric Acute
Liver Failure**

James E. Squires¹; Estella M. Alonso²; Samar H. Ibrahim³; Vania Kasper⁴; Mohit Kehar⁵;
Mercedes Martinez⁶; Robert H. Squires¹

¹ Division of Gastroenterology, Hepatology and Nutrition, UPMC Children's Hospital of Pittsburgh, Pittsburgh, Pennsylvania, USA

² Pediatric Hepatology, Ann and Robert H Lurie Children's Hospital, Chicago, Illinois, USA.

³ Department of Pediatrics, Division of Pediatric Gastroenterology and Hepatology, Mayo Clinic, Rochester, Minnesota, USA

⁴ Division of Pediatric Gastroenterology, Nutrition and Liver Diseases, Hasbro Children's Hospital, Providence, Rhode Island, USA

⁵ Division of Pediatric Gastroenterology, Hepatology and Nutrition, Children Hospital of Eastern Ontario, Ottawa, Ontario, Canada

⁶ Department of Pediatrics, Vagelos College of Physician and Surgeons, Columbia University, New York, New York, USA

Corresponding Author:

James E Squires MD, MS

Division of Gastroenterology, Hepatology and Nutrition

Children's Hospital of Pittsburgh

One Children's Hospital Drive, 6th Floor FP

4401 Penn Avenue

Pittsburgh PA 15224

Phone: 412-692-5180; Fax: 412-692-7355

Email address: James.Squires2@chp.edu

DISCLAIMER:

NASPGHAN is not responsible for the practices of physicians and provides guidelines and position papers as indicators of best practice only. Diagnosis and treatment is at the discretion of physicians.

Financial Support:

The authors report no external sources of funding were utilized for the purposes of the research presented.

Conflicts of Interest:

None

What is Known

- The clinical presentation and progression of PALF is variable and rapid decline occurs often
- An age-based diagnostic approach to identify the potential underlying cause is of utmost importance to initiate appropriate lifesaving therapy
- Etiology-specific treatment and general management focusing on preventing complications may help to mitigate disease progression and avoid liver transplant

What is New

- The current manuscript provides clinical guidance to pediatric gastroenterologists and other pediatric providers caring for children with PALF by presenting the most recent advances in diagnosis, management, pathophysiology, and associated outcomes

Abstract

Pediatric acute liver failure (PALF) is a rare, rapidly progressive clinical syndrome with significant morbidity and mortality. The phenotype of PALF manifests as abrupt onset liver dysfunction which can be brought via disparate etiology. Management is reliant upon intensive clinical care and support, often provided by the collaborative efforts of hepatologists, critical care specialists, and liver transplant surgeons. The construction of an age-based diagnostic approach, the identification of a potential underlying cause, and the prompt implementation of appropriate therapy can be lifesaving. However, the dynamic and rapidly progressive nature of PALF also demands that diagnostic inquiries be paired with monitoring strategies for the recognition and treatment of common complications of PALF. While liver transplantation can provide a potential life-saving therapeutic option, the ability to confidently determine the certainty that liver transplant is needed for an individual child has been hampered by a lack of adequately tested clinical decision support tools and accurate

predictive models. Given the accelerated progress in understanding PALF, we will provide clinical guidance to pediatric gastroenterologists and other pediatric providers caring for children with PALF by presenting the most recent advances in diagnosis, management, pathophysiology, and associated outcomes.

I. Introduction and Historical Perspective

Acute liver failure (ALF), a rare clinical condition with significant morbidity and mortality, has captured the curiosity of clinicians and pathologists for centuries. The French physician, and father of modern epidemiology, Guillaume de Baillou (Ballonius), is credited with the initial description of ALF in 1616 of a boy “of noble birth” whose course of fever, jaundice, delirium, and seizures ended in death after 15 days (1). It was not until 1842 that Carl von Rokitansky, an Austrian pathologist, provided the classic description of acute yellow atrophy (AYA) of the liver (a.k.a Rokitansky disease) (2, 3). Subsequent reports of AYA emphasized its rarity, but a 1947 unauthored editorial from the Journal of the American Medical Association identified three waves of AYA with different suspected etiologies: 1.) 1918-1924 (post- World War I) was thought to be due to Arshenamine introduced in 1910 to treat syphilis and African trypanosomiasis, 2.) 1928-1934; attributed to cinchophen, an analgesic introduced in 1908 to treat gout, and 3.) “during and after World War II” thought to be due to viral hepatitis transmitted by plasma or improperly sterilized needles (4).

The modern era of ALF observational studies likely began in 1964 when the term “massive hepatic necrosis” (MHN) replaced AYA in a paper by Rodgers et al. presenting a retrospective analysis of autopsies performed at Boston City Hospital from January 1, 1953, to July 1, 1963 (5). Over those 10 years, 18 cases of MHN were identified among 11,341 autopsies with ages ranging from 12-84 years. Etiologies included viral hepatitis (N=5), exposure to blood products at surgery (N=4), drug toxicity (N=2), alcoholism (N=1), and indeterminate (N=6). Subsequently, the Fulminant Hepatic Failure (FHF) Surveillance Study was organized to include 73 centers. Subjects were enrolled based upon criteria proposed by Trey and Davidson that included patients with hepatic failure who developed hepatic coma within 8 weeks of the onset of illness and presumed to have normal liver function before the start of symptoms (6). While children accounted for a small portion of enrollment, they observed the contribution of halothane, presumed infectious hepatitis, serum hepatitis, and Reye Syndrome as causes of FHF in children <14 years (7).

Beginning in 1980, retrospective single-site descriptions of children with FHF or ALF slowly emerged from London (8), Los Angeles (9), and Bicetre (10) reporting etiology and outcomes. As interest in ALF grew along with challenges associated with single-center

reports (11), the National Institutes of Health (NIH) and National Institutes of Diabetes, Digestive, and Kidney Disorders (NIDDK) funded a national consortium to prospectively enroll adults (12) and later, children (13) with ALF. World-wide interest in pediatric ALF (PALF) has remained high with contributions from developed and developing countries highlighting national and regional differences and experiences. Given the accelerated progress in understanding PALF, we intend to present the most recent advances in diagnosis, management, pathophysiology, and outcomes associated with PALF.

II. Epidemiology, Clinical Features, and Natural History of PALF:

PALF Defined: Historically, children were assigned an ALF diagnosis based upon the adult definition that included hepatic encephalopathy (HE). Recognizing the challenge of accurate HE assessment in infants and children, the PALF Study Group (PALFSG) utilized consensus entry criteria for their longitudinal study enabling enrollment without HE (13). (**Table 1**) These criteria were not intended to establish a definitive diagnosis, but rather to identify subjects with acute liver injury sufficiently severe to place the child at risk for a progressive clinical deterioration that could result in liver transplantation (LT) or death. Over time, these criteria have gained broader acceptance and are now widely used to determine appropriateness for inclusion into research studies and guide clinical management (14). Importantly, the PALF phenotype may represent an acute presentation of chronic disease (Wilson disease, autoimmune hepatitis, etc.), prompting efforts to reconsider these criteria to initiate optimal interventions (chelation, immunosuppression, etc.) that may impact prognosis and management in these cases (15, 16).

Incidence: The overall incidence of PALF is unknown; however, population-wide rates are estimated at 500-600 cases per year in the United States (US). PALF in the U.S. does not vary by region and has been stable over the last decade (17).

The incidence in developing countries is suspected to be higher due to increased rates of infectious hepatitis (18). Improvements in health management can affect incidence and etiology. For example, in Argentina, implementing a Hepatitis A virus (HAV) immunization program resulted in a drop of transplant listing rates due to HAV from 60% to 0% (15).

Clinical Signs and Symptoms: The clinical presentation of PALF varies based on age and etiology. Frequently, a prodromal phase with non-specific symptoms of fatigue, malaise, nausea, and abdominal pain is elicited. (**Figure 1**) A history of fever is occasionally reported. Children may have been seen by medical providers and offered supportive or empiric therapies without improvement. Identification of liver disease may not occur until jaundice becomes clinically apparent, or clinical decline prompts liver function testing. While a precise timeline of symptoms is important, it is often difficult to ascertain, and may not correlate with onset of liver injury.

Important historical information: Initial appearance of jaundice should be elicited if possible. Perceived change in behavior or attention that may reflect the development of HE should be

identified. Additional historical elements should include factors associated with common etiologies of PALF. (**Table 2**) Etiology does vary by age and history should be directed appropriately.

Initial physical exam findings: Physical exam may be normal in the early stages of ALF. However, initial, and serial neurological examinations should be performed to assess mental (e.g., attentiveness, confusion, orientation) and neurological (e.g., brisk reflexes, Babinski sign) signs of HE. Signs on initial examination suggestive of an underlying chronic liver disease are essential and can be grouped by organ system. (**Table 3**)

Natural History: The clinical course of PALF is rapid, dynamic, and unpredictable. The interval between presentation and a clinical outcome, such as LT, death, or spontaneous recovery, can be as short as a few hours or days for some children. Thus, there is an urgency in establishing a specific diagnosis as a timely therapeutic intervention can affect clinical outcomes. In the era before LT, the dynamic natural history of PALF was for children to either survive or die, although worsening clinical course did not preclude a favorable outcome. The introduction of LT provided a potentially life-saving intervention; however, it is prudent to underscore that LT arbitrarily interrupts the natural course of PALF and it is accepted that some patients who receive a LT may have survived without one. (**Figure 1**) Given the insufficient number of organs to satisfy patient needs, there is a critical need for more precise method to identify those patients who will survive without a liver transplant, as well as those who will die despite a liver transplant.

III. Diagnosis, Management Strategies, and Monitoring in Children:

A patient meeting PALF study entry criterion (**Table 1**) should initiate general management strategies regardless of etiology. (**Figure 2**) Once the most appropriate setting for clinical care has been established, a 4-pronged coordinated management and diagnostic approach should be conducted to inform clinical decisions: 1) liver-specific tests to assess the degree of inflammation, injury, and function; 2) general tests to assess hematological, renal, pancreatic, neurologic, and electrolyte co-morbidities; 3) laboratory and physical exam based assessment strategy for evolving complication of PALF, and 4) age-based diagnostic investigations to establish an etiology as quickly as possible to inform treatment decisions. (**Table 4**)

A common challenge relates to the volume of blood needed from a pediatric patient. As almost 50% of PALF occurs in children under 4 years of age, limitations on the volume of blood that can be drawn demands a knowledgeable prioritization of tests that needs to be communicated to medical, nursing, and phlebotomy teams. In addition, required blood work in preparation for a liver transplant also competes for this limited resource. Additional challenges that may preclude a complete diagnostic and medical evaluation include a rapid clinical trajectory ending in death or LT (**Figure 1**), a differential diagnosis that is incomplete or not prioritized, or clinical improvement that mitigates diagnostic curiosity.

Clinical and Histological Assessment: A laboratory and clinical assessment plan should be commenced immediately and occur at least twice per day initially, then adjusted based upon trends and interventions. Importantly, the presence and degree of HE is critical in

determining appropriate management. (**Table 4**) It should be a priority to identify conditions contraindicated in LT, amenable to specific therapy, or that inform subsequent pregnancies. Liver biopsy poses several challenges related to bleeding risk and concerns that findings may not sufficiently inform treatment decisions. However, recent reports demonstrate it can be performed safely, especially when the transvenous (e.g., transjugular) approach is feasible and results used to guide diagnosis and therapy (19). This is of particular importance in children with indeterminate PALF (IND-PALF), where histology has identified distinct patterns suggesting immune mediated liver injury (20, 21). (see Immune Mediated section below)

Management of common complications in PALF: Close, multi-disciplinary collaboration between gastroenterology/hepatology, intensive care, neurology, neurosurgery, nephrology, metabolic disease specialists as well as transplant surgeons will afford the child the best opportunity to survive. While specific etiologies may warrant more precise, targeted therapy (see Etiology section below), common co-morbidities in PALF warrant consideration of a generalized approach. (**Table 5**)

Fluids and electrolytes: In the presence of cardiovascular instability, fluid or colloid resuscitation should be prioritized. In the absence of the need for volume resuscitation, total intravenous fluids should initially be restricted to around 90% of maintenance fluids to avoid overhydration. Initial fluids should be similar to hypertonic glucose (D10) one-half normal saline and supplemented with 15 mEq of potassium (K⁺)/L. Fluids with pre-determined concentrations of electrolytes, such as Lactated Ringers, should be avoided. Glucose infusion rates as high as 10–15 mg/min per kg body weight may be required to achieve stable serum glucose levels (between 90 and 120 mg/dl) and typically require administration of hypertonic glucose solutions via a central catheter. Hypophosphatemia can be profound and requires supplementation to maintain serum phosphorus levels above 3 mg/dL. Over-hydration can precipitate pulmonary and peripheral edema, ascites, and cerebral edema, while under-hydration can precipitate hepatorenal syndrome (50), acute tubular necrosis, worsening encephalopathy, and hypotension.

Hepatic encephalopathy and hyperammonemia: All children with PALF should be clinically evaluated for evidence and severity of hepatic encephalopathy (HE). (**Table 6**) HE is challenging to assess and may not be clinically apparent, particularly in infants and young children (53). An altered mental status due to severe illness, metabolic decompensation, electrolyte abnormality, cardiovascular instability, or fear may confound the assessment of HE (52). However, the determination of HE remains critical as its presence and severity guides clinical assessment (**Table 4**) and often drives additional cardiovascular and respiratory support. Definitive pathogenesis continues to be debated, and various toxins have been implicated, including bile acids, aromatic amino acids, cytokines, and chemokines; however, amongst all potential causative agents, ammonia assumes an essential role (32). While arterial ammonia measurement is ideal, it is not practical in children with stage 0–II HE; venous ammonia obtained from a free-flowing catheter and promptly placed on ice and transported to the laboratory may be a suitable substitute. An ammonia of 75 $\mu\text{mol/L}$ is an

important threshold below which patients rarely develop intracranial hypertension. Conversely, ammonia levels of $>100 \mu\text{mol/L}$ on admission represent an independent risk factor for the development of high-grade HE (54), and a level of $>200 \mu\text{mol/L}$ is strongly associated with cerebral herniation (55). Therefore, medical therapy targeting ammonia reduction is often prescribed (**Table 5**). Lactulose may be favored over Rifaximin given its mechanism of action and shorter time to clinical effect; however, no definitive data suggests that either impact clinical outcomes. Still, mechanisms driving HE development extend beyond an elevated ammonia alone to include markers associated with systemic inflammation and neuroinflammation (56, 57). Therefore, reliance upon a singular ammonia value to determine the presence of HE should be avoided, its measurement supporting the clinical assessment of the child at the bedside.

Cerebral edema: Cerebral edema (CE) with resultant increased intracranial pressure (ICP) is a life-threatening complication of ALF and is the most common terminal event related to HE. It occurs most commonly in those with advanced HE (grade III or IV) and can be rapidly progressive. Ammonia level $> 200 \mu\text{mol/L}$ is a known risk factor for mortality (58) and can manifest clinically as abnormal pupillary responses, paroxysmal hypertension, hyperreflexia, and positive Babinski sign. Surgical placement of a pressure transducer within the cranial vault (an ICP “bolt”) is the most sensitive test to detect ICP elevations but is recognized to carry its own risk for the patient with an uncorrectable coagulopathy with bleeding complications noted between 10–20% (59). Additionally, children may be at increased risk for complication development given their relatively thin skull vault (36). Given the limited data on invasive ICP monitoring in PALF and the lack of evidence demonstrating bolt insertion affects outcomes, the decision to place an ICP monitor is often case-specific. Fever can contribute to cerebral hyperemia and can be treated with a cooling blanket to maintain euthermia. Electroencephalogram (EEG) is indicated for any myoclonus/seizure-like activity, or sudden mental status deterioration. Hemodynamic support with dopamine or norepinephrine is implemented to assure a cerebral perfusion pressure adequate for age. (**Table 5**)

Coagulopathy/Bleeding: Both prothrombin time (PT) and the international normalized ratio (INR) are elevated in PALF and are markers for severe hepatocellular dysfunction. Notably, abnormalities in these synthetic markers do not equate with bleeding risk in PALF as both procoagulant proteins (e.g., factors V, VII, and X and fibrinogen) and anticoagulant proteins (e.g., antithrombin, protein C, and protein S) are reduced (46, 60). Indeed, some children may have manifestations of a hypercoagulable state (e.g., portal vein thrombosis) (61). Still, clinically significant bleeding can occur in PALF often precipitated by sepsis. Initial management should look to improve the abnormality via administration of an age- and weight-appropriate dose of vitamin K ranging from 1 mg in infants to 10 mg in older adolescents. Oral vitamin K therapy should not be used to correct the INR in PALF. Rather, subcutaneous administration should be used to ensure administration. Intramuscular and intravenous vitamin K have also been used, but these routes carry a Black Box warning for rare, but potentially serious side effects. Coagulopathy secondary to vitamin K deficiency should rapidly correct following appropriate repletion. Notably, if coagulopathy persists,

efforts to ‘correct’ abnormal coagulation profiles with fresh frozen plasma or other pro-coagulation product should generally be avoided. Plasma transfusions transiently improve laboratory measures but have no proven benefit when given prophylactically and can instead contribute to volume overload. Most centers will use plasma and/or platelet infusions prior to an invasive procedure, such as liver biopsy or ICP monitor placement, or in the setting of life-threatening bleeding. Thrombocytopenia related to consumption or bone marrow suppression can occur. Thromboelastography (TEG) is designed to incorporate all coagulation phases and has promise to inform management decisions but requires additional study.

Kidney injury: The etiology for renal dysfunction in PALF is commonly linked to acute kidney injury (AKI) resulting from nephrotoxic medication exposure (e.g., NSAIDs) or systemic hypotension secondary to sepsis or hemorrhage. As PALF generally occurs in children who were thought to be previously healthy, most renal injury is presumed to be acute in nature and otherwise recoverable. Patients may require continuous veno-venous hemofiltration or renal replacement therapy to maintain fluid balance when renal function is impaired. In patients with renal dysfunction secondary to hepatorenal syndrome (50), recovery parallels improvement in liver function; for those with direct kidney injury the course can be more prolonged.

Infection: Patients with ALF have an enhanced susceptibility to bacterial infection and sepsis from immune system dysfunction (14). Evidence of infection may be subtle, such as tachycardia, bleeding (e.g., intestinal, pulmonary), reduced renal output, or mental status changes. Fever may not be present. Blood cultures should be obtained with any evidence of clinical deterioration and antibiotics initiated with a clinical concern for sepsis.

Cardiovascular dysfunction/failure: Many patients with overwhelming liver injury will develop hemodynamic instability independent of infectious complications. Serum cytokine levels likely contribute to systemic vasodilation and cardiac dysfunction. Hypotension can negatively impact cerebral perfusion and should be avoided. Echocardiograms can be helpful in assessing cardiac output and vascular tone. Relative adrenal insufficiency has been described in adults with ALF and should be considered in the setting of refractory hypotension.

Nutritional support: Patients with PALF are likely catabolic and require more calories than basal needs. Enteral feeding is often preferred over total parenteral nutrition (TPN), and both naso-gastric or naso-jejunal feeds should be considered before TPN. Still, TPN may be needed to provide maximal calories with minimal volume depending on the overall fluid status or if glucose control becomes problematic. In cases where TPN is deemed appropriate, protein restriction (1 g/kg protein daily) can be considered if hyperammonemia is present. Additionally, lipids should be utilized unless a disorder of fatty acid oxidation or mitochondrial disease is suspected (23, 49, 62, 63).

Liver support therapies: Various iterations of extracorporeal liver support systems have been investigated in children with ALF to determine if they might have a measurable impact on

clinical outcome. Unfortunately, virtually all of them, including albumin dialysis, plasma exchange, bioartificial liver support systems (BAL; human hepatoblastoma cells), extracorporeal liver assist device (ELAD[®]; human-based cells), HapatAssist[®] (porcine cell-based), and molecular absorbent recirculating system (MARS), have fallen short of the mark or have been underpowered to assess benefit. Therefore, they cannot be routinely recommended (32, 64).

Plasmapheresis/Plasma exchange: In adult ALF, high-volume plasma exchange has been shown to have a positive impact on transplant-free survival; the benefit being to remove hepatotoxic substances in the blood while enhancing liver regeneration (65). Evidence of its usefulness in children with ALF is sparse, and while coagulation profiles may improve, the procedure has not been shown to improve neurologic outcomes or ameliorate spontaneous recovery. At most, studies in pediatrics have shown plasmapheresis, at times in combination with other extracorporeal therapies, may serve as a bridge to transplant (64, 66-68).

Molecular Absorbent Recirculating System (MARS): The molecular adsorbent recirculating system utilizes a membrane with albumin-related binding sites that separates the patients' blood from an albumin dialysate to remove albumin-bound substances (e.g., bilirubin, aromatic amino acids, and endogenous benzodiazepine-like substances) as well as free low-molecular-weight molecules (e.g., ammonia). Despite theoretical benefits, MARS has not demonstrated significant benefit in PALF other than a potential bridge for patients with severe liver trauma to spontaneous recovery (69). There is a paucity of data in children using MARS, but in a cohort of 20 children with ALF who were MARS-treated, biochemical parameters such as ammonia, bilirubin, and creatinine improved, and it appeared to be safe (70). However, the heterogeneous patient cohort precluded a more rigorous statistical analysis for benefit. Adequately powered studies are essential to determine if children receive a meaningful benefit from MARS.

IV. Liver Transplant in PALF

In the pre-LT era, outcomes from PALF were binary as patients either survived with their native liver or died. PALF was a devastating process, with mortality rates ranging from 70% to 95% (71, 72). With the advent and advancement of pediatric LT, a third outcome was introduced, providing a potentially life-saving therapeutic option for children with PALF. The success of LT in PALF is reflected in its use, whereby up to 10.3% of all pediatric LT are now performed in the setting of PALF (73).

Prognostic Scores and Liver Transplant Decisions: PALF is a rapidly evolving clinical condition with no current satisfactory tools to predict outcomes. While improved prognostic models capable of predicting outcome would greatly benefit the community, efforts to construct such a model are ironically hampered by LT. Most models incorporate both death and LT into a single outcome. Notably, these two outcomes are not equivalent as the LT population includes patients who may have lived (or died) had LT not intervened. Existing models such as Kings College Hospital Criteria and the Liver Injury Unit score that combined

outcomes were not validated when death and LT outcomes were separated (74, 75). Analyses investigating the interconnectedness of various dynamic inflammatory networks do appear to segregate outcomes of death and survival and also demonstrated those who received a LT had a mixed picture, with inflammatory network similarities to both the survival and death cohorts (76, 77). Additional efforts using a growth mixture model that included clinical data (INR, encephalopathy, total bilirubin) collected over 7 days identified different trajectories that were associated with differing likelihoods for death or survival (78) and other models using the trajectory of data collected over time suggest dynamic models hold some promise (79-81). Still, significant limitations to the current prognostic models persist and decisions to pursue LT remain complex, based on the alignment of physician experience, clinical assessment, and suitable organ availability. Ultimately, when a liver transplant is performed in the setting of PALF, outcomes have shown to be inferior compared to children with other chronic liver disease requiring transplant (82), underscoring opportunities for further investigation and improvement.

V. Etiology Specific Mechanisms of Injury, Clinical Characteristics, and Treatment

Specific etiologies of PALF can be broadly categorized as infectious, immunologic, metabolic, and toxin/drug related, and age-based differences are recognized. However, an identified cause for liver injury is lacking in approximately 30% - 50% of cases (13, 83). **Figure 3** details the causes of ALF in 1144 children enrolled in the PALFSG from 19 pediatric liver transplant centers in the USA, Canada, and the UK between 1999 and 2014. In developing countries, the etiologies are similar but are dominated by infectious etiologies, with hepatitis A virus (HAV) being the most common identified etiology (84, 85). This brief summation of processes that can cause PALF should be supplemented by other sources detailing each specific disease state.

Immune mediated: Immune dysregulation contributes to the pathogenesis of many liver injuries in children. Importantly, the presence of autoantibodies alone is non-specific and can be present in a variety of disease states, most notably Wilson disease, drug-induced injury, and indeterminate (86). Still, recognizing immune dysregulation driving PALF development and progression is critical as immunomodulating therapies can be effective in these patients.

Autoimmune Hepatitis/Auto-antibody positive ALF: Classic serological markers associated with autoimmune liver disease, which include anti-nuclear antibody (ANA), smooth muscle antibody (SMA), and liver-kidney microsomal (LKM) antibody, are positive in 28% of children with ALF (86) and the diagnosis of autoimmune hepatitis (AIH) should generally be considered in any patient outside the neonatal period presenting with ALF (87). Classic elevations in serum globulins may not be present and histology typically suggests features of AIH (plasma cell-enriched portal tract infiltrate, interface hepatitis, central perivenulitis, and lymphoid follicles) but without evidence of chronicity (88). Corticosteroids can mitigate liver injury in many patients and while steroid treatment did not improve survival overall in auto-antibody positive children, the sub-group of patients with a known diagnosis of AIH had improved outcomes (86).

Gestational Alloimmune Liver Disease (GALD): GALD results from an intrauterine alloimmune liver injury and is suspected to be the single most common cause of neonatal acute liver failure (89). Mechanistically, a to-be-determined hepatocyte-specific fetal antigen is thought to cross the placenta, inducing maternal immunoglobulin G production, which then returns to the fetal circulation, activates fetal complement, and results in the formation of the membrane attack complex (MAC) and subsequent liver cell injury (90). Therefore, while appearing as an ‘acute’ event associated with liver failure, it is technically a terminal event of a chronic intrauterine liver disease.

Characteristic clinical features of GALD include an ALF presentation usually at birth and almost always in the first days of life. The majority (70% – 90%) of affected infants are born premature and a history of maternal sibling death is common. Medical history often reveals intrauterine growth restriction and oligohydramnios. Refractory hypoglycemia, severe coagulopathy, hypoalbuminemia, elevated serum ferritin (>1000 µg/L), and ascites are often noted. Strikingly, serum aminotransferase levels are normal or near normal and should alert the clinician to the possibility of GALD (89). Extrahepatic iron deposition (often on MRI or buccal biopsy) and positive MAC staining in liver tissue suggest the diagnosis; however, these findings have been reported in other disease states as well, limiting their specificity for GALD (91). Timely exchange transfusion and high-dose intravenous immunoglobulin (IVIG) is the preferred treatment to remove offending antibodies and block their action, including activation of complement (89, 92). The mechanism of GALD places subsequent pregnancies at risk, and intrapartum IVIG should be used to prevent recurrences.

Hemophagocytic Lymphohistiocytosis (HLH): is an enigmatic syndrome describing patients with severe hyperinflammation. Characteristic features include fever, hepatosplenomegaly, cytopenias, hypertriglyceridemia, hyperferritinemia, and hypofibrinogenemia. Clinically, children can develop hepatitis, coagulopathy, and liver failure in addition to extrahepatic manifestations such as central nervous system involvement and multiorgan failure (93). Various sub-categories have been described (primary, secondary, familial, etc.). There is a growing understanding of the genetic underpinnings that can both drive disease and predispose individuals to its development. Recognition of the disease state should prompt extensive investigations into possible triggers (infection, malignancy, rheumatologic disease, etc.), and treatment consists of immunosuppressive agents and chemotherapeutic drugs and biologics that aim to dampen the inflammatory state and treat any underlying etiology (93).

Indeterminate PALF/T-cell activated Hepatitis: When a specific diagnosis is not established in PALF, these children are categorized as indeterminate (IND-PALF). Likely, the indeterminate group consists of some patients who underwent an incomplete diagnostic evaluation and while almost 43% of the overall PALFSG participants were categorized as indeterminate (**Figure 3**), the incorporation of standardized diagnostic test recommendations into electronic medical record order sets enabled a significant reduction in the percentage of IND-PALF, from 48% during the first 2 phases of the study (1999 – 2010) to 30.8% when looking at phase 3 (2011 – 2014) (94).

Mechanisms driving injury have been postulated to occur secondary to overzealous inflammatory responses and immune dysregulation (83). This has been supported by noting increasing inflammatory network connectivity in these patients in addition to clinical biomarkers of immune dysregulation that have been associated with poorer outcomes (76, 95, 96).

Recent attempts to better characterize IND-PALF have uncovered a unique sub-set of IND-PALF patients who have distinctive liver histology, including a dense CD103+CD8+ T-cell infiltrate, further suggesting an immune-mediated liver injury (20, 21, 97). Based on these observations, there has been a growing trend toward treating PALF associated with activated CD8+ T cell hepatitis with immunosuppression. However, the therapeutic benefit of this practice remains unknown (98).

Drug-induced liver injury: Drug-induced liver injury (DILI) is the leading cause of ALF in adults and the most common identifiable cause in children (94). (**Figure 3**). Given the complexity of DILI, the NIH-supported Drug-Induced Liver Injury Network (DILIN), has and continues to standardize the terminology and causality assessment of DILI, including those associated with liver failure. As part of this effort, the website LiverTox® (<http://livertox.nlm.nih.gov/index.html>) was launched as a joint effort of the Liver Disease Research Branch of the NIDDK and the Division of Specialized Information Services of the National Library of Medicine. The purpose of LiverTox® is to provide up-to-date, accurate, and easily accessed information on the diagnosis, cause, frequency, patterns, and management of liver injury attributable to medications, herbals, and dietary supplements.

Evaluation of DILI includes an assessment of clinical and laboratory features, clinical pattern of liver injury (hepatocellular, cholestatic or mixed), the clinical course after cessation of the suspected drug, assessment of risk factors (age, sex, obesity), exclusion of underlying liver diseases, previous episodes of DILI, liver biopsy, and in some cases drug re-challenge to establish causality. Notably, drug re-challenge should specifically be avoided in DILI-associated PALF.

Acetaminophen (APAP): APAP is one of the most frequently used medications, remains the most common cause of DILI, and is the most common identified cause of ALF in children (94, 99). Two clinical scenarios are associated with acetaminophen hepatotoxicity: 1.) the most common follows a single intentional ingestion of a hepatotoxic dose and 2.) a scenario where patients inadvertently partake in a ‘therapeutic misadventure’, unintentionally taking multiple doses of APAP and/or APAP-containing medications at or above therapeutic recommendations over several days (100). In children, single acute ingestion of > 150 mg/kg has been considered potentially toxic and may cause severe liver injury, including ALF (101). Mechanistically, suprathreshold APAP ingestion depletes glutathione stores resulting in necrosis and cell death with the predominance of injury in hepatic zone 3. Clinical signs and symptoms of acetaminophen toxicity occur in 4 stages following ingestion. (**Table 7**)

When the timing of acute ingestion is known, the Rumack-Mathews nomogram is used to plan treatment and the risk of hepatotoxicity. N-Acetylcysteine (NAC) should be started if the serum acetaminophen level is greater than 10 mg/mL or if transaminase levels are elevated. NAC is an effective antidote for APAP poisoning, which provides cysteine to replenish and maintain hepatic glutathione stores. Notably, broader NAC administration in PALF was not shown to be beneficial in non-APAP PALF (102) and thus its use should be reserved where APAP toxicity has been confirmed or highly suspected.

In a setting where the diagnosis is unclear, APAP protein adduct assessment has shown promise. These protein adducts lead to mitochondrial dysfunction, promote oxidant stress, and high levels of protein adducts have been detected in the serum of patients with APAP overdose (103). However, this testing is not currently commercially available.

Prognosis is excellent in the majority of children with APAP induced PALF and timely use of NAC. Liver transplantation may be needed and is lifesaving in severely ill patients who do not respond to treatment with NAC, reported in 5% of children (104).

Non-APAP medications: Liver injury caused by drugs other than APAP was identified in a little more than 3% of cases in the PALFSG registry, the vast majority occurring in children over 10 years of age (13, 94). Anti-epileptics are the most common offenders in children (13, 105). Valproic acid, particularly in children with unsuspected mitochondrial disease, may precipitate ALF. In this setting valproic acid-associated liver failure should be a contraindication for LT (106). The list of non-APAP drugs associated with liver failure is extensive and expanding. A partial list is found in **Table 8**.

Herbals and dietary supplements (HDS): Liver injury associated with the consumption of herbal medicines and dietary supplements is often referred to as ‘herb-induced liver injury’ (HILI) (130). Herbals and dietary supplements are used world-wide, often without any proven health benefits. These products are perceived to be safe owing to their inclusion of botanical and natural ingredients; however, this also leads to alternative regulations and oversight. In the U.S., these substances are regulated as food products and not subjected to the same premarket requirements for safety or efficacy when compared to traditional pharmaceutical agents. Establishing a diagnosis of HILI is challenging since many of the products contain multiple ingredients (131). Common agents implicated with PALF include Kava (132), willow bark tea (133), *Atractylis gummifera* (134), green tea (135), *Teucrium polium* (136), pennyroyal oil (137), Chaparral (138), Impila, and other Pyrrolizidine Alkaloids (139) and weight loss supplements predominately in adult patients (140).

Metabolic and Genetic Diseases: Metabolic liver diseases collectively account for 28-36% of cases of PALF (141, 142). Common culprits are galactosemia, tyrosinemia, Niemann-Pick type C, mitochondrial hepatopathies, and urea cycle defects in infants and young children and Wilson’s disease in older children. Family history of consanguinity, recurrent abortions and sibling deaths, and patient history of diarrhea, vomiting, failure to thrive or developmental

delay, all adds to the index of suspicion. Accurate diagnosis and timely therapeutic intervention can be life-saving (143).

Wilson's disease: Wilson's disease (WD) is the most common metabolic condition associated with PALF in children over five years of age and is typically fatal without LT (13). The presence of Coombs-negative hemolytic anemia, hyperbilirubinemia, low serum ceruloplasmin, marked elevation of serum copper > 200 microg/dL, and a normal or low serum alkaline phosphatase should raise the concern about WD. Among patients presenting with acute liver failure, Kayser-Fleischer rings are present in approximately half. Elevated copper content (above 250 mcg/g dry weight liver) remains the gold standard for diagnosis when feasible (144). Plasma exchange, continuous hemodiafiltration, Zinc, and copper chelation therapy have been employed in patients with Wilson disease presenting with ALF and stage I to II hepatic encephalopathy, while pursuing a liver transplant evaluation with some success (145).

Tyrosinemia: Hereditary tyrosinemia (HT) type 1 is an autosomal recessive disease caused by a deficiency of fumarylacetoacetate hydrolase (FAH), the last enzyme of the tyrosine catabolic pathway. The acute form of the disease is characterized by an early onset of PALF with profound coagulopathy and normal or near-normal serum aminotransferase levels (142, 146). HT1 often presents in association with gram-negative sepsis. Tyrosinemia is included in the newborn screen, and early identification with initiation of nitisinone and dietary modifications have improved outcomes (147, 148).

Galactosemia: Impaired activity of galactose-1-phosphate uridyltransferase (GALT) causes galactosemia, an autosomal recessive disorder of galactose metabolism. Galactosemia can present in association with gram-negative sepsis. It should be considered in infants consuming breast milk or another lactose-containing formula who develop ALF associated with reducing substances in the urine (149). Galactosemia is included in the newborn screen; however, affected infants may become symptomatic before newborn screen results are available. Early initiation of a galactose-restricted diet can prevent or resolve neonatal complications. Definitive diagnosis is made by the quantitative assay of GALT activity in red blood cells. Therefore, blood for diagnostic testing must be obtained prior to any red blood cell transfusion (150).

Urea Cycle Defects: Urea cycle disorders (UCDs) are inborn errors in the nitrogen detoxification pathway's metabolism and encompass six principal enzymatic deficiencies. Direct toxicity of metabolites, downstream metabolic deficiencies, impaired tricarboxylic acid cycle, oxidative stress, mitochondrial dysfunction, and energy deficit contribute to liver injury (151). Ornithine transcarbamylase deficiency (OTCD) is the most common of the urea cycle disorders and follows an X-linked inheritance pattern, although heterozygous females can be affected. PALF with OTCD is recognized. In a Swiss cohort of 37 patients with OTCD, 50% had ALF at least once(152). In a historical cohort of 49 OTCD patients with liver involvement, ALF's prevalence was highest with ammonia levels >1000 µmol/L. ALF was the initial presenting symptom of OTCD in 6% of the patients (153). Treatment is based

on ammonia scavengers (benzoate and phenylacetate /phenylbutyrate) and a protein-restricted diet (154).

Citrullinemia type I is an autosomal recessive UCD caused by a deficiency of arginosuccinate synthetase, which typically presents in the neonatal period or infancy with hyperammonemia and neurologic deterioration. Fulminant liver failure associated with catabolic stress has been reported in isolated cases with good response to supportive therapy (155, 156).

Hyperargininemia is an autosomal recessive UCD caused by a deficiency of arginase 1, which catalyzes the hydrolysis of L-arginine to urea as the final enzyme in the urea cycle. Arginase 1 deficiency does not usually cause severe neonatal hyperammonemia but instead presents with progressive neurological symptoms, including seizures and spastic paraplegia in the first years of life associated with neonatal cholestasis, and ALF (157).

Fatty Acid Oxidation Disorders: Mitochondrial fatty acid oxidation disorders (FAOD) are recessively inherited errors of metabolism, which include among others medium-chain acyl-CoA dehydrogenase (MCAD) deficiency, fatty acid transportation defects, and defects of beta-oxidation enzymes. Newborns with FAOD typically present following a minor febrile illness, fasting or dehydration with hypoketotic hypoglycemia, metabolic acidosis, hepatic dysfunction that may evolve into ALF, and cardiomyopathy. Hyperammonemia may also occur. Screening studies include measurements of urinary organic acid and plasma carnitine levels with acylcarnitine profiles. Confirmation requires functional studies in cultured skin fibroblasts or genetic studies. The sharp decline in the incidence of Reye's syndrome is attributed in part to improved diagnosis of FAOD and avoidance of salicylates used in febrile children. The mainstay of therapy during acute decompensation includes continuous intravenous glucose infusion (10 mg/kg/min to maintain serum glucose above 100 mg/dL); avoidance of intravenous lipid and drugs that inhibit FAO such as valproic acid, nonsteroidal anti-inflammatory agents and salicylates; and L-carnitine administration enterally or intravenously at a dose of 100 mg/kg/day (158, 159). If possible, screening studies should be obtained prior to glucose administration as biochemical markers may return to normal quickly after the treatment is started.

Mitochondrial Hepatopathy: Genetic and acquired alterations in mitochondrial structure and function are increasingly recognized as the etiology for various pathologic conditions termed mitochondrial disorders (MD). Hepatic disease is estimated to occur in up to 20% of patients with MD and is more commonly seen in early childhood (160). These mitochondrial hepatopathies (MH) are defined by dysfunction of hepatocyte mitochondria leading to cell injury, steatosis, or liver failure as major manifestations of disease (161-163). Multisystem mitochondrial dysfunction has historically served as a relative contraindication to liver transplant (164). However, patients with mitochondrial diseases (excluding POLG related disease) have more recently been shown to tolerate solid-organ transplant with post-transplant survival similar to non-mitochondrial disease patients (165). Unfortunately, multisystem involvement may not be apparent at liver transplant, and progressive extra-hepatic disease can occur. Lactic acidosis and an elevated molar ratio of lactate to pyruvate (>25 mol/mol) have historically been used to alert the clinician to the possibility of a

mitochondrial hepatopathy; however, recent analysis of the PALFSG cohort found that neither an elevated serum lactate ≥ 2.5 mmol/L nor an elevated lactate:pyruvate (L:P) ratio were specific for mitochondrial disease in the setting of PALF and elevation did not predict clinical outcome (166). Thus, it appears that secondary mitochondrial dysfunction, independent of the cause of acute liver failure, may drive lactate and L:P abnormalities in PALF and that neither diagnosis nor clinical decisions (including considerations for liver transplant) should be based solely on these findings (166). Expedited whole-exome sequencing is the most precise diagnostic tool to reach this diagnosis, though variable geographic availability limits universal application.

Others (NBAS, LARS, hereditary fructose intolerance, etc.): A growing category of autosomal recessive monogenic disorders affecting intracellular trafficking and vesicles transport is emerging as a significant contributor to the undiagnosed patients with ALF. Bi-allelic mutations in Neuroblastoma amplified sequence (NBAS), SCYL1, and RINT1 are among the identified etiologies. These disorders present with a fever-induced liver injury that might evolve into recurrent ALF. Extrahepatic manifestations include short stature, skeletal abnormalities, intellectual disability, ophthalmic abnormalities, low serum immunoglobulins, facial dysmorphism, and cardiac abnormalities in NBAS associated disorders (167). Patients with SCYL1-associated disease may present with recurrent low GGT cholestasis or fever-triggered acute liver failure with onset in infancy and a variable neurological phenotype of later onset. Liver injury is usually transient, but fibrosis may develop (168). Some reported patients with RINT1 bi-allelic mutations have a persistent abnormality of liver function tests between episodes. Supportive therapy is the mainstay of managing these disorders. Early antipyretic therapy may prevent recurrent episodes of ALF; however, liver transplantation has been performed in 2 patients with fever-triggered recurrent ALF caused by NBAS pathogenic variants without recurrence of ALF post-transplant (169).

LARS gene encodes a cytoplasmic leucyl-tRNA synthetase enzyme responsible for attaching leucine to its cognate tRNA during protein translation. Homozygosity mapping and exome sequencing identified LARS mutation as the underlying etiology of ALF in six individuals from an Irish family presenting with ALF in the first few months of life. The patients developed acute symptoms and deterioration of liver function with minor illness with intermittent improvement between episodes. The earliest age of presentation was 2 months, and the oldest affected member of this family was 33 years. Additional symptoms include anemia, renal tubulopathy, developmental delay, seizures, and failure to thrive. (170).

Hereditary fructose intolerance (HFI) is an autosomal recessive disorder caused by aldolase B (ALDOB) deficiency resulting in the inability to metabolize fructose. The toxic accumulation of intermediate fructose-1-phosphate causes multiple metabolic disturbances, including postprandial hypoglycemia, lactic acidosis, electrolyte disturbance, liver, and kidney dysfunction. The clinical presentation varies depending on the age of exposure and the load of fructose. Most cases present at the age of weaning, when fructose or sucrose is added to the infant's diet. However, exposure to a formula containing fructose is an important trigger for severe metabolic disturbances evolving into a life-threatening ALF. Treatment is mainly

supportive, based on intravenous dextrose, and fructose-free formula. HFI is not included in the newborn screen, as there is no readily available biochemical marker for screening without fructose exposure (171).

Niemann-Pick type C is a lysosomal storage disease. Most individuals present with progressive neurologic disease in middle to late childhood, a minority of cases present during early infancy with acute liver failure. Therapy is usually palliative given the progressive neurological disease. Rapid whole exome sequencing can be helpful in a timely diagnosis and the decision making about the need for liver transplantation (172).

Viral Hepatitis: Viral hepatitis usually exhibits a benign course in childhood; however, severe illnesses may be seen. Viral infections were implicated as a possible etiology in several reports of PALF: in studies from Asia, viral hepatitis was identified as the etiology 46% - 94% of the time (18), just over 8% of the PALFSG registry were identified as having a viral etiology (94). Circumstantial evidence, such as prodromal viral-type symptoms, observed in many cases, supports a viral insult as a preceding event in ALF. Nevertheless, many remain asymptomatic, especially small children and neonates. Screening for common forms of viral hepatitis, including Hepatitis A, B, and C, is performed frequently, but testing for viruses less often considered hepatotropic is not universally performed. Furthermore, the demonstration of a viral pathogen does not necessarily imply causality. The fatality rate for viral-associated acute liver failure ranged from 3%-91%, the highest reported in developing countries. The need for liver transplantation with viral-associated acute liver failure ranged from 4% to 62% (173). Early detection utilizing newer diagnostic techniques, such as real-time polymerase chain reaction (PCR), and prompt institution of specific therapy will improve survival and reduce the need for transplantation.

Hepatitis A: Hepatitis A Virus (HAV) is a cytopathic, non-enveloped, single-stranded RNA virus with 4 genotypes characterized in humans. HAV infections are seen worldwide with greater prevalence in developing countries and low-income regions (174). It is transmitted primarily by the fecal-oral route in contaminated food or water, with an incubation period of 15-50 days. (175, 176). Patients with HAV infection usually present with one of the following clinical patterns: 1.) asymptomatic without jaundice; 2.) symptomatic with jaundice and self-limiting course; 3.) prolonged cholestatic pattern; 4.) relapsing pattern and 5.) ALF, occurring in less than 1% of patients with acute HAV infection (177, 178). HAV infection is the most common cause of PALF in Asia, parts of Europe, and Latin America (84, 179-185), but not in developed countries (13, 186). The diagnosis of acute HAV infection is based on the detection of IgM antibodies against HAV. No specific medications are available to treat acute hepatitis A. LT may be required in severe cases, and referral to a transplant center is critical for patients of HAV-associated PALF.

Hepatitis E: Hepatitis E virus (HEV) belongs to the Hepeviridae family of viruses, under the genus Hepevirus. Usually, the infection is self-limiting and resolves within 2–6 weeks, presenting with acute icteric hepatitis. In a small proportion of patients, the disease is severe and associated with ALF with worse outcomes in pregnant women, particularly in the second

and third trimesters (187, 188). The diagnosis is confirmed by the presence of anti-HEV IgM antibody and positive HEV RNA in the serum. Data on antiviral agents (Ribavirin) have not been systematically evaluated in patients with severe acute hepatitis E/ALF and is limited to case reports (189).

Hepatitis B: Hepatitis B virus (HBV) is highly prevalent in the WHO Western Pacific Region and WHO African Region, where 6.2% and 6.1% of the adult population is infected, respectively (190). Vertical and early horizontal transmissions are the main routes of HBV transmission in children. The majority of children with acute hepatitis B have an asymptomatic or subclinical illness; however, in endemic regions, up to 65% of cases of PALF are related to acute HBV infection (191). Rarely, infants born to mothers with chronic HBV infection can also present with PALF (192, 193). Patients with acute hepatitis B test positive for HBsAg and IgM anti-HBc, and during the early phase, HBeAg and HBV DNA will also be present. The use of antiviral agents in acute HBV is debatable (194, 195) but is recommended in severe cases/PALF to reduce recurrent HBV risk after LT (196). The prognosis of HBV-related ALF is poor without LT, with transplant-free survival rates ranging from 26% to 53% (197, 198), and urgent referral to LT center is of paramount importance.

Herpes simplex virus: HSV is recognized as a common cause of neonatal liver failure (199). Affected infants present with symptoms resembling sepsis and may have skin, eye, or mouth lesions. The lack of skin lesions or symptoms in the infant or mother does not exclude the diagnosis (200). In a registry study from the United States, HSV was identified in 25% of young infants who underwent testing and was frequently fatal in this age group (201). HSV-associated liver failure carries high mortality in the neonatal period (202), but it is medically treatable with timely initiation of effective antivirals (200). LT in conjunction with antiviral therapy can be life-saving (203).

Epstein-Barr virus: Epstein-Barr virus (EBV) is the primary cause of infectious mononucleosis (IM) with a lifetime prevalence of 90% (204, 205). The majority of patients with acute EBV infection have mild hepatitis manifesting as elevated serum aminotransferase up to 2 to 3 times the upper limit of normal (206). The enzyme levels typically rise over a 1- to 2-week period, and levels are lower than seen in patients with acute hepatitis A, B, D, or E. Most cases have a hepatocellular injury; however, mixed or cholestatic injury features have also been reported in the literature (207, 208). Acute EBV infection can rarely be complicated by severe hepatitis leading to PALF, resulting in death or LT (209-221). EBV diagnosis should be based on a combination of clinical features, serology, and confirmatory PCR testing. A liver biopsy may be required to confirm the diagnosis of EBV hepatitis in selected cases with in situ hybridizations of EBV-encoded RNA (EBER) (222).

Cytomegalovirus: Cytomegalovirus (CMV) is one of the human herpesviruses commonly spread through intrauterine transmission from mother to child. CMV usually causes chronic cholestatic disease and, less frequently, neonatal liver failure (201). CMV-associated liver disease can be efficiently treated with several available antivirals in immunocompetent and immunodeficient children (223).

Adenovirus: Human adenovirus is a double-stranded, nonenveloped DNA virus, with more than 50 phenotypes that exhibit tissue-specific tropism (224). Serotypes 40 and 41 have been associated with gastrointestinal manifestations, most frequently self-limited diarrhea, although rare cases of fulminant hepatitis have been reported mainly in immunosuppressed hosts (225-227). Despite being an unusual presentation for liver failure, a high mortality rate has been described if the diagnosis and treatment are not offered before irreversible insult has occurred (227). Treatment with antiviral and liver transplantation can be lifesaving (226-228).

Enteroviruses: The enteroviruses are a family of a single-stranded positive RNA that includes several genera. The infection is primarily transmitted by the fecal-oral route and can also spread via the respiratory tract. Clinical manifestations are genus-specific and vary from asymptomatic to severe. Small children and neonates are at significantly increased risk for severe disease. Among a cohort of children < 6 months, enterovirus was responsible for 23% of liver failure (201). There are no current therapies to treat enterovirus infections.

Other viruses: In the context of the rapidly evolving pandemic of the severe acute respiratory syndrome, coronavirus-2 (SARS-CoV-2), a few cases of PALF have been reported, mostly with spontaneous recovery (229). Possible mechanism of the hepatic injury in these complex patients includes viral-induced cytopathogenic effect in the liver (230), ischemia, and drug-induced liver injury.

Cardiovascular: Ischemic liver injury can cause acute liver failure. Lack of perfusion typically results from systemic hypotension due to shock, sepsis, Budd-Chiari syndrome (BCS), veno-occlusive disease (VOD), cardiac dysfunction (e.g., hypoplastic left heart syndrome, cardiomyopathy, cardiopulmonary bypass), or the use of vasoactive drugs. Hypoperfusion associated with PALF accounts for roughly 3% of reported cases (94, 231).

VOD is a clinical entity characterized by weight gain, hepatomegaly, ascites, and hyperbilirubinemia (bilirubin > 2mg/dl) caused by hepatic sinusoidal obstruction, mostly after hematopoietic stem cell transplantation (HSCT) (232). The primary reported risk factors are related to the type and doses of chemotherapy agents. Survival has improved with the implementation of protocols avoiding hepatotoxic drugs and the recent introduction of effective therapies such as Defibrotide (233). The majority of BCS patients present with a chronic course, characterized by the insidious onset of abdominal distension, portal hypertension (PHT), and tortuous engorged abdominal veins (234). The acute or fulminant presentation with abdominal pain, hepatomegaly, ascites, and rapidly progressive hepatic failure is uncommon. This cohort of patients usually have an underlying prothrombotic condition and require an emergency evaluation for TIPS and/or liver transplantation (235).

Oncologic: Hematological malignancies, such as leukemia and lymphoma, can rarely present with ALF (236, 237). Diagnostic clues for hematological malignancies include high fever, hepatosplenomegaly, elevated alkaline phosphatase, lactate dehydrogenase, and peripheral blood film abnormalities. A bone marrow examination may be diagnostic. Acute hepatic

failure can also occur after metastatic liver infiltration due to neuroblastoma or other solid tumors (238). Evaluation of liver histology may be needed, despite the risk of bleeding in patients with coagulopathies. Despite these rare occurrences, it is essential to consider malignant infiltration of the liver given the clear contraindication of liver transplantation, which could otherwise be lifesaving in failure due to other etiologies.

VI. Conclusion and General Recommendations

Data-driven advances in diagnosis, management, and mechanistic understanding of PALF have been exponential over the last two decades. Outcomes in non-LT survival in PALF have improved. This has been due, in large part, to productive national and international collaborations, many of which were supported by the NIH/NIDDK. In addition, the general adaptation of study criteria used to identify PALF patients has improved our ability to compare descriptive, diagnostic, therapeutic, and mechanistic studies performed by investigators worldwide.

As is always the case, there is much more to be accomplished. Diagnostic studies, now requiring unacceptable blood volume in critically ill infants and children, may someday be replaced with “gene/diagnostic chip” technology with a rapid turn-around to affect life-saving treatments. Improvements in neuromonitoring may transform our ability to provide preemptive treatment for HE and cerebral edema. Clinically useful personalized models that reliably predict dynamic patient outcomes would transform liver transplant decisions. Adequately powered randomized clinical trials that examine new or novel therapeutics will provide foundational support for evidence-based clinical management.

The commitment of clinical, translational, and basic researchers worldwide to pursue important and unanswered questions related to PALF is inspiring. Their work will impact the lives of children afflicted with PALF and inform future guidelines and position statements. We look forward to their upcoming observations and discoveries.

General Recommendations:

- PALF is a complex, rapidly evolving clinical syndrome, children meeting diagnostic criteria should be considered for early contact/transfer to an experienced pediatric liver transplant center when indicated. (**Figure 2**)
- Children meeting diagnostic criteria for PALF warrant careful laboratory and clinical monitoring in a pediatric intensive care unit. (**Table 4**)
- A timely, age-based diagnostic approach (**Table 4**) should be used to establish an etiology and inform treatment decisions.
- Once PALF has been established, general management strategies should be undertaken to monitor for (**Table 4**) and manage (**Table 5**) common complications regardless of the etiology.

References

1. Cockayne EA. Catarrhal jaundice, sporadic and epidemic, and its relation to acute yellow atrophy of the liver. *QJM*. 1912;6(1):1-29.
2. Jay V. The legacy of Karl Rokitansky. *Arch Pathol Lab Med*. 2000;124(3):345-6.
3. Kahn M, Barsky J. Acute yellow atrophy of the liver. *Arch Intern Med*. 1921;28(2):9.
4. JAMA E. Acute yellow atrophy of the liver. *JAMA*. 1947;133(15):2.
5. Rodgers JB, Mallory GK, Davidson CS. Massive liver cell necrosis. *Archives of Internal Medicine*. 1964;114(Nov):9.
6. Trey C, Davidson CS. The management of fulminant hepatic failure. *Prog Liver Dis*. 1970;3:282-98.
7. Trey C. The fulminant hepatic failure surveillance study. Brief review of the effects of presumed etiology and age of survival. *Can Med Assoc J*. 1972;106:525-8.
8. Psacharopoulos HT, Mowat AP, Davies M, Portmann B, Silk DB, Williams R. Fulminant hepatic failure in childhood: an analysis of 31 cases. *Arch Dis Child*. 1980;55(4):252-8.
9. Rivera-Penera T, Moreno J, Skaff C, McDiarmid S, Vargas J, Ament ME. Delayed encephalopathy in fulminant hepatic failure in the pediatric population and the role of liver transplantation. *J Pediatr Gastroenterol Nutr*. 1997;24(2):128-34.
10. Durand P, Debray D, Mandel R, Baujard C, Branchereau S, Gauthier F, et al. Acute liver failure in infancy: a 14-year experience of a pediatric liver transplantation center. *J Pediatr*. 2001;139(6):871-6.
11. Hoofnagle JH, Carithers RL, Jr., Shapiro C, Ascher N. Fulminant hepatic failure: summary of a workshop. *Hepatology*. 1995;21(1):240-52.
12. Ostapowicz G, Fontana RJ, Schiodt FV, Larson A, Davern TJ, Han SH, et al. Results of a prospective study of acute liver failure at 17 tertiary care centers in the United States. *Ann Intern Med*. 2002;137(12):947-54.
13. Squires RH, Jr., Shneider BL, Bucuvalas J, Alonso E, Sokol RJ, Narkewicz MR, et al. Acute liver failure in children: the first 348 patients in the pediatric acute liver failure study group. *J Pediatr*. 2006;148(5):652-8.
14. Squires JE, McKiernan P, Squires RH. Acute Liver Failure: An Update. *Clin Liver Dis*. 2018;22(4):773-805.

15. Mendizabal M, Dip M, Demirdjian E, Lauferman L, Lopez S, Minetto J, et al. Changing Etiologies and Prognostic Factors in Pediatric Acute Liver Failure. *Liver Transpl.* 2020;26(2):268-75.
16. Di Giorgio A, Nicasastro E, Dalla Rosa D, Nebbia G, Sonzogni A, D'Antiga L. Transplant-free Survival in Chronic Liver Disease Presenting as Acute Liver Failure in Childhood. *Transplantation.* 2019;103(3):544-51.
17. Kulkarni S, Perez C, Pichardo C, Castillo L, Gagnon M, Beck-Sague C, et al. Use of Pediatric Health Information System database to study the trends in the incidence, management, etiology, and outcomes due to pediatric acute liver failure in the United States from 2008 to 2013. *Pediatr Transplant.* 2015;19(8):888-95.
18. Anand AC, Nandi B, Acharya SK, Arora A, Babu S, Batra Y, et al. Indian National Association for the Study of Liver Consensus Statement on Acute Liver Failure (Part-2): Management of Acute Liver Failure. *J Clin Exp Hepatol.* 2020;10(5):477-517.
19. Chapin CA, Mohammad S, Bass LM, Taylor SA, Kelly S, Alonso EM. Liver Biopsy Can Be Safely Performed in Pediatric Acute Liver Failure to Aid in Diagnosis and Management. *J Pediatr Gastroenterol Nutr.* 2018;67(4):441-5.
20. Chapin CA, Burn T, Meijome T, Loomes KM, Melin-Aldana H, Kreiger PA, et al. Indeterminate pediatric acute liver failure is uniquely characterized by a CD103(+) CD8(+) T-cell infiltrate. *Hepatology.* 2018;68(3):1087-100.
21. McKenzie RB, Berquist WE, Nadeau KC, Louie CY, Chen SF, Sibley RK, et al. Novel protocol including liver biopsy to identify and treat CD8+ T-cell predominant acute hepatitis and liver failure. *Pediatr Transplant.* 2014;18(5):503-9.
22. Srinivasan A, Venkataraman S, Hansdak SG, Abraham OC, Mathai D. Hyperglycaemia as an indicator of concurrent acute pancreatitis in fulminant hepatic failure associated with hepatitis B infection. *Singapore Med J.* 2005;46(5):236-7.
23. Lutfi R, Abulebda K, Nitu ME, Molleston JP, Bozic MA, Subbarao G. Intensive Care Management of Pediatric Acute Liver Failure. *J Pediatr Gastroenterol Nutr.* 2017;64(5):660-70.
24. Gonda DD, Meltzer HS, Crawford JR, Hilfiker ML, Shellington DK, Peterson BM, et al. Complications associated with prolonged hypertonic saline therapy in children with elevated intracranial pressure. *Pediatr Crit Care Med.* 2013;14(6):610-20.
25. Baquerizo A, Anselmo D, Shackleton C, Chen TW, Cao C, Weaver M, et al. Phosphorus as an early predictive factor in patients with acute liver failure. *Transplantation.* 2003;75(12):2007-14.

26. Gluud LL, Vilstrup H, Morgan MY. Nonabsorbable disaccharides for hepatic encephalopathy: A systematic review and meta-analysis. *Hepatology*. 2016;64(3):908-22.
27. Wijdicks EF. Hepatic Encephalopathy. *N Engl J Med*. 2016;375(17):1660-70.
28. Acharya SK, Bhatia V, Sreenivas V, Khanal S, Panda SK. Efficacy of L-ornithine L-aspartate in acute liver failure: a double-blind, randomized, placebo-controlled study. *Gastroenterology*. 2009;136(7):2159-68.
29. Sidhu SS, Sharma BC, Goyal O, Kishore H, Kaur N. L-ornithine L-aspartate in bouts of overt hepatic encephalopathy. *Hepatology*. 2017.
30. Stravitz RT, Gottfried M, Durkalski V, Fontana RJ, Hanje AJ, Koch D, et al. Safety, tolerability, and pharmacokinetics of l-ornithine phenylacetate in patients with acute liver injury/failure and hyperammonemia. *Hepatology*. 2018;67(3):1003-13.
31. Shawcross DL, Wendon JA. The neurological manifestations of acute liver failure. *Neurochem Int*. 2012;60(7):662-71.
32. Zoica BS, Deep A. Extracorporeal renal and liver support in pediatric acute liver failure. *Pediatr Nephrol*. 2020.
33. Kodali S, McGuire BM. Diagnosis and Management of Hepatic Encephalopathy in Fulminant Hepatic Failure. *Clin Liver Dis*. 2015;19(3):565-76.
34. Young AM, Guilfoyle MR, Donnelly J, Scoffings D, Fernandes H, Garnett M, et al. Correlating optic nerve sheath diameter with opening intracranial pressure in pediatric traumatic brain injury. *Pediatr Res*. 2017;81(3):443-7.
35. Maloney PR, Mallory GW, Atkinson JL, Wijdicks EF, Rabinstein AA, Van Gompel JJ. Intracranial Pressure Monitoring in Acute Liver Failure: Institutional Case Series. *Neurocrit Care*. 2016;25(1):86-93.
36. Hunt A, Tasker RC, Deep A. Neurocritical care monitoring of encephalopathic children with acute liver failure: A systematic review. *Pediatr Transplant*. 2019;23(7):e13556.
37. Stevens RD, Shoykhet M, Cadena R. Emergency Neurological Life Support: Intracranial Hypertension and Herniation. *Neurocrit Care*. 2015;23 Suppl 2:S76-82.
38. Bernal W, Murphy N, Brown S, Whitehouse T, Bjerring PN, Hauerberg J, et al. A multicentre randomized controlled trial of moderate hypothermia to prevent intracranial hypertension in acute liver failure. *J Hepatol*. 2016;65(2):273-9.

39. Karvellas CJ, Todd Stravitz R, Battenhouse H, Lee WM, Schilsky ML, Group USALFS. Therapeutic hypothermia in acute liver failure: a multicenter retrospective cohort analysis. *Liver Transpl.* 2015;21(1):4-12.
40. Tofteng F, Larsen FS. The effect of indomethacin on intracranial pressure, cerebral perfusion and extracellular lactate and glutamate concentrations in patients with fulminant hepatic failure. *J Cereb Blood Flow Metab.* 2004;24(7):798-804.
41. Coles JP, Minhas PS, Fryer TD, Smielewski P, Aigbirihio F, Donovan T, et al. Effect of hyperventilation on cerebral blood flow in traumatic head injury: clinical relevance and monitoring correlates. *Crit Care Med.* 2002;30(9):1950-9.
42. Francony G, Fauvage B, Falcon D, Canet C, Dilou H, Lavagne P, et al. Equimolar doses of mannitol and hypertonic saline in the treatment of increased intracranial pressure. *Crit Care Med.* 2008;36(3):795-800.
43. Koenig MA, Bryan M, Lewin JL, 3rd, Mirski MA, Geocadin RG, Stevens RD. Reversal of transtentorial herniation with hypertonic saline. *Neurology.* 2008;70(13):1023-9.
44. Argo CK, Balogun RA. Blood products, volume control, and renal support in the coagulopathy of liver disease. *Clin Liver Dis.* 2009;13(1):73-85.
45. Krisl JC, Meadows HE, Greenberg CS, Mazur JE. Clinical usefulness of recombinant activated factor VII in patients with liver failure undergoing invasive procedures. *Ann Pharmacother.* 2011;45(11):1433-8.
46. Lisman T, Stravitz RT. Rebalanced Hemostasis in Patients with Acute Liver Failure. *Semin Thromb Hemost.* 2015;41(5):468-73.
47. Schneider J, Khemani R, Grushkin C, Bart R. Serum creatinine as stratified in the RIFLE score for acute kidney injury is associated with mortality and length of stay for children in the pediatric intensive care unit. *Crit Care Med.* 2010;38(3):933-9.
48. Cardoso FS, Gottfried M, Tujios S, Olson JC, Karvellas CJ, Group USALFS. Continuous renal replacement therapy is associated with reduced serum ammonia levels and mortality in acute liver failure. *Hepatology.* 2017.
49. European Association for the Study of the Liver. Electronic address eee, Clinical practice guidelines p, Wendon J, Panel m, Cordoba J, Dhawan A, et al. EASL Clinical Practical Guidelines on the management of acute (fulminant) liver failure. *J Hepatol.* 2017;66(5):1047-81.
50. Liu PMF, de Carvalho ST, Fradico PF, Cazumba MLB, Campos RGB, Simoes ESAC. Hepatorenal syndrome in children: a review. *Pediatr Nephrol.* 2020.

51. Whittington PF AA. Fulminant hepatitis and acute liver failure. Paediatric Liver Disease. Blackwell: Oxford 2003. p. 107–26.
52. Squires RH, Jr. Acute liver failure in children. Semin Liver Dis. 2008;28(2):153-66.
53. Ng VL, Li R, Loomes KM, Leonis MA, Rudnick DA, Belle SH, et al. Outcomes of Children With and Without Hepatic Encephalopathy From the Pediatric Acute Liver Failure Study Group. J Pediatr Gastroenterol Nutr. 2016;63(3):357-64.
54. Bernal W, Hall C, Karvellas CJ, Auzinger G, Sizer E, Wendon J. Arterial ammonia and clinical risk factors for encephalopathy and intracranial hypertension in acute liver failure. Hepatology. 2007;46(6):1844-52.
55. Clemmesen JO, Larsen FS, Kondrup J, Hansen BA, Ott P. Cerebral herniation in patients with acute liver failure is correlated with arterial ammonia concentration. Hepatology. 1999;29(3):648-53.
56. Butterworth RF. The liver-brain axis in liver failure: neuroinflammation and encephalopathy. Nat Rev Gastroenterol Hepatol. 2013;10(9):522-8.
57. Toney NA, Bell MJ, Belle SH, Hardison RM, Rodriguez-Baez N, Loomes KM, et al. Hepatic Encephalopathy in Children With Acute Liver Failure: Utility of Serum Neuromarkers. J Pediatr Gastroenterol Nutr. 2019;69(1):108-15.
58. Acute liver failure linked to felbamate use. Am J Hosp Pharm. 1994;51(23):2882, 7.
59. Kamat P, Kunde S, Vos M, Vats A, Gupta N, Heffron T, et al. Invasive intracranial pressure monitoring is a useful adjunct in the management of severe hepatic encephalopathy associated with pediatric acute liver failure. Pediatr Crit Care Med. 2012;13(1):e33-8.
60. Kawada PS, Bruce A, Massicotte P, Bauman M, Yap J. Coagulopathy in Children With Liver Disease. J Pediatr Gastroenterol Nutr. 2017;65(6):603-7.
61. Barton CA. Treatment of Coagulopathy Related to Hepatic Insufficiency. Crit Care Med. 2016;44(10):1927-33.
62. Plauth M, Schuetz T, Working group for developing the guidelines for parenteral nutrition of The German Association for Nutritional M. Hepatology - Guidelines on Parenteral Nutrition, Chapter 16. Ger Med Sci. 2009;7:Doc12.
63. Kerwin AJ, Nussbaum MS. Adjuvant nutrition management of patients with liver failure, including transplant. Surg Clin North Am. 2011;91(3):565-78.
64. Jain V, Dhawan A. Extracorporeal Liver Support Systems in Paediatric Liver Failure.

- J Pediatr Gastroenterol Nutr. 2017;64(6):855-63.
65. Larsen FS, Schmidt LE, Bernsmeier C, Rasmussen A, Isoniemi H, Patel VC, et al. High-volume plasma exchange in patients with acute liver failure: An open randomised controlled trial. *J Hepatol.* 2016;64(1):69-78.
 66. Kiss JE, Berman D, Van Thiel D. Effective removal of copper by plasma exchange in fulminant Wilson's disease. *Transfusion.* 1998;38(4):327-31.
 67. Singer AL, Olthoff KM, Kim H, Rand E, Zamir G, Shaked A. Role of plasmapheresis in the management of acute hepatic failure in children. *Ann Surg.* 2001;234(3):418-24.
 68. Akcan Arikan A, Srivaths P, Himes RW, Tufan Pekkucuksen N, Lam F, Nguyen T, et al. Hybrid Extracorporeal Therapies as a Bridge to Pediatric Liver Transplantation. *Pediatr Crit Care Med.* 2018;19(7):e342-e9.
 69. Hanish SI, Stein DM, Scalea JR, Essien EO, Thurman P, Hutson WR, et al. Molecular Adsorbent Recirculating System Effectively Replaces Hepatic Function in Severe Acute Liver Failure. *Ann Surg.* 2017;266(4):677-84.
 70. Lexmond WS, Van Dael CM, Scheenstra R, Goorhuis JF, Sieders E, Verkade HJ, et al. Experience with molecular adsorbent recirculating system treatment in 20 children listed for high-urgency liver transplantation. *Liver Transpl.* 2015;21(3):369-80.
 71. Psacharopoulos HT, Mowat AP, Davies M, Portmann B, Silk DB, Williams R. Fulminant hepatic failure in childhood: an analysis of 31 cases. *Arch Dis Child.* 1980;55(4):252-8.
 72. Mondragon R, Mieli-Vergani G, Heaton ND, Mowat AP, Vougas V, Williams R, et al. Liver transplantation for fulminant liver failure in children. *Transpl Int.* 1992;5 Suppl 1:S206-8.
 73. Kim WR, Lake JR, Smith JM, Schladt DP, Skeans MA, Noreen SM, et al. OPTN/SRTR 2017 Annual Data Report: Liver. *Am J Transplant.* 2019;19 Suppl 2:184-283.
 74. Lu BR, Zhang S, Narkewicz MR, Belle SH, Squires RH, Sokol RJ, et al. Evaluation of the liver injury unit scoring system to predict survival in a multinational study of pediatric acute liver failure. *J Pediatr.* 2013;162(5):1010-6 e4.
 75. Sundaram V, Shneider BL, Dhawan A, Ng VL, Im K, Belle S, et al. King's College Hospital Criteria for Non-Acetaminophen Induced Acute Liver Failure in an International Cohort of Children. *J Pediatr.* 2013;162(2):319-23 e1.

76. Azhar N, Ziraldo C, Barclay D, Rudnick DA, Squires RH, Vodovotz Y, et al. Analysis of serum inflammatory mediators identifies unique dynamic networks associated with death and spontaneous survival in pediatric acute liver failure. *PLoS One*. 2013;8(11):e78202.
77. Zamora R, Vodovotz Y, Mi Q, Barclay D, Yin J, Horslen S, et al. Data-Driven Modeling for Precision Medicine in Pediatric Acute Liver Failure. *Mol Med*. 2016;22.
78. Li R, Belle SH, Horslen S, Chen LW, Zhang S, Squires RH, et al. Clinical Course among Cases of Acute Liver Failure of Indeterminate Diagnosis. *J Pediatr*. 2016;171:163-70 e1-3.
79. Rajanayagam J, Frank E, Shepherd RW, Lewindon PJ. Artificial neural network is highly predictive of outcome in paediatric acute liver failure. *Pediatr Transplant*. 2013;17(6):535-42.
80. Kumar R, Shalimar, Sharma H, Goyal R, Kumar A, Khanal S, et al. Prospective derivation and validation of early dynamic model for predicting outcome in patients with acute liver failure. *Gut*. 2012;61(7):1068-75.
81. Lee EJ, Kim JW, Moon JS, Kim YB, Oh SH, Kim KM, et al. Development of a Prognostic Score to Predict Mortality in Patients With Pediatric Acute Liver Failure. *J Pediatr Gastroenterol Nutr*. 2020;70(6):777-82.
82. Farmer DG, Venick RS, McDiarmid SV, Duffy JP, Kattan O, Hong JC, et al. Fulminant hepatic failure in children: superior and durable outcomes with liver transplantation over 25 years at a single center. *Ann Surg*. 2009;250(3):484-93.
83. Alonso EM, Horslen SP, Behrens EM, Doo E. Pediatric acute liver failure of undetermined cause: A research workshop. *Hepatology*. 2017;65(3):1026-37.
84. Alam S, Khanna R, Sood V, Lal BB, Rawat D. Profile and outcome of first 109 cases of paediatric acute liver failure at a specialized paediatric liver unit in India. *Liver Int*. 2017;37(10):1508-14.
85. Tannuri AC, Porta G, Kazue Miura I, Santos MM, Moreira Dde A, de Rezende NM, et al. Pediatric acute liver failure in Brazil: Is living donor liver transplantation the best choice for treatment? *Liver Transpl*. 2016;22(7):1006-13.
86. Narkewicz MR, Horslen S, Belle SH, Rudnick DA, Ng VL, Rosenthal P, et al. Prevalence and Significance of Autoantibodies in Children With Acute Liver Failure. *J Pediatr Gastroenterol Nutr*. 2017;64(2):210-7.
87. Mack CL, Adams D, Assis DN, Kerkar N, Manns MP, Mayo MJ, et al. Diagnosis and Management of Autoimmune Hepatitis in Adults and Children: 2019 Practice

- Guidance and Guidelines From the American Association for the Study of Liver Diseases. *Hepatology*. 2019.
88. Stravitz RT, Lefkowitz JH, Fontana RJ, Gershwin ME, Leung PS, Sterling RK, et al. Autoimmune acute liver failure: proposed clinical and histological criteria. *Hepatology*. 2011;53(2):517-26.
 89. Taylor SA, Whittington PF. Neonatal acute liver failure. *Liver Transpl*. 2016;22(5):677-85.
 90. Larson-Nath C, Vitola BE. Neonatal Acute Liver Failure. *Clin Perinatol*. 2020;47(1):25-39.
 91. Wu H, Ferguson W, Castro E, Kearney D, Finegold M, Patel K. Extrahepatic Nonreticuloendothelial Siderosis Is Not Specific to Gestational Alloimmune Liver Disease. *Pediatr Dev Pathol*. 2019;22(4):356-64.
 92. Fischer HS, Staufner C, Sallmon H, Henning S, Buhner C. Early Exchange Transfusion to Treat Neonates With Gestational Alloimmune Liver Disease: An 11-Year Cohort Study. *J Pediatr Gastroenterol Nutr*. 2020;70(4):444-9.
 93. Canna SW, Marsh RA. Pediatric hemophagocytic lymphohistiocytosis. *Blood*. 2020;135(16):1332-43.
 94. Narkewicz MR, Horslen S, Hardison RM, Shneider BL, Rodriguez-Baez N, Alonso EM, et al. A Learning Collaborative Approach Increases Specificity of Diagnosis of Acute Liver Failure in Pediatric Patients. *Clin Gastroenterol Hepatol*. 2018;16(11):1801-10 e3.
 95. Zamora R, Vodovotz Y, Mi Q, Barclay D, Yin J, Horslen S, et al. Data-Driven Modeling for Precision Medicine in Pediatric Acute Liver Failure. *Mol Med*. 2017;22:821-9.
 96. Leonis MA, Miethke AG, Fei L, Maynor S, Chapin CA, Bleasing JJH, et al. Four biomarkers linked to activation of CD8+ lymphocytes predict clinical outcomes in pediatric acute liver failure. *Hepatology*. 2020.
 97. Chapin CA, Melin-Aldana H, Kreiger PA, Burn T, Neighbors K, Taylor SA, et al. Activated CD8 T-cell Hepatitis in Children with Indeterminate Acute Liver Failure: Results from a Multicenter Cohort. *J Pediatr Gastroenterol Nutr*. 2020.
 98. Chapin CA, Horslen SP, Squires JE, Lin H, Blondet N, Mohammad S, et al. Corticosteroid Therapy for Indeterminate Pediatric Acute Liver Failure and Aplastic Anemia with Acute Hepatitis. *J Pediatr*. 2019.

99. Narkewicz MR, Dell Olivo D, Karpen SJ, Murray KF, Schwarz K, Yazigi N, et al. Pattern of diagnostic evaluation for the causes of pediatric acute liver failure: an opportunity for quality improvement. *J Pediatr*. 2009;155(6):801-6 e1.
100. Lee WM. Acetaminophen (APAP) hepatotoxicity-Isn't it time for APAP to go away? *J Hepatol*. 2017;67(6):1324-31.
101. Prescott LF. Paracetamol overdosage. Pharmacological considerations and clinical management. *Drugs*. 1983;25(3):290-314.
102. Squires RH, Dhawan A, Alonso E, Narkewicz MR, Shneider BL, Rodriguez-Baez N, et al. Intravenous N-acetylcysteine in pediatric patients with nonacetaminophen acute liver failure: a placebo-controlled clinical trial. *Hepatology*. 2013;57(4):1542-9.
103. Alonso EM, James LP, Zhang S, Squires RH, Pediatric Acute Liver Failure Study G. Acetaminophen Adducts Detected in Serum of Pediatric Patients With Acute Liver Failure. *J Pediatr Gastroenterol Nutr*. 2015;61(1):102-7.
104. Mahadevan SB, McKiernan PJ, Davies P, Kelly DA. Paracetamol induced hepatotoxicity. *Arch Dis Child*. 2006;91(7):598-603.
105. Devarbhavi H, Patil M, Reddy VV, Singh R, Joseph T, Ganga D. Drug-induced acute liver failure in children and adults: Results of a single-centre study of 128 patients. *Liver Int*. 2018;38(7):1322-9.
106. Mindikoglu AL, King D, Magder LS, Ozolek JA, Mazariegos GV, Shneider BL. Valproic acid-associated acute liver failure in children: case report and analysis of liver transplantation outcomes in the United States. *J Pediatr*. 2011;158(5):802-7.
107. Shi Q, Yang X, Greenhaw JJ, Salminen AT, Russotti GM, Salminen WF. Drug-Induced Liver Injury in Children: Clinical Observations, Animal Models, and Regulatory Status. *Int J Toxicol*. 2017;36(5):365-79.
108. Singhal S, Gray T, Guzman G, Verma A, Anand K. Sevoflurane hepatotoxicity: a case report of sevoflurane hepatic necrosis and review of the literature. *Am J Ther*. 2010;17(2):219-22.
109. Metushi IG, Cai P, Zhu X, Nakagawa T, Utrecht JP. A fresh look at the mechanism of isoniazid-induced hepatotoxicity. *Clin Pharmacol Ther*. 2011;89(6):911-4.
110. Wu SS, Chao CS, Vargas JH, Sharp HL, Martin MG, McDiarmid SV, et al. Isoniazid-related hepatic failure in children: a survey of liver transplantation centers. *Transplantation*. 2007;84(2):173-9.
111. Kumar R, Shalimar, Bhatia V, Khanal S, Sreenivas V, Gupta SD, et al.

- Antituberculosis therapy-induced acute liver failure: magnitude, profile, prognosis, and predictors of outcome. *Hepatology*. 2010;51(5):1665-74.
112. Huguet A, Ader F, Ohlmann C, Collardeau-Frachon S, Gillet Y. Drug-Induced Fulminant Hepatitis in a Child Treated for Latent Multidrug-Resistant Tuberculosis With Dual Therapy Combining Pyrazinamide and Levofloxacin. *Pediatr Infect Dis J*. 2019;38(10):1025-6.
 113. Ohkawa K, Hashiguchi M, Ohno K, Kiuchi C, Takahashi S, Kondo S, et al. Risk factors for antituberculous chemotherapy-induced hepatotoxicity in Japanese pediatric patients. *Clin Pharmacol Ther*. 2002;72(2):220-6.
 114. Fontana RJ, Shakil AO, Greenson JK, Boyd I, Lee WM. Acute liver failure due to amoxicillin and amoxicillin/clavulanate. *Dig Dis Sci*. 2005;50(10):1785-90.
 115. Fish J, Ingram D, Walkiewicz-Jedrzejczak D. Fulminant Liver Failure Presenting Shortly After Initiation of Doxycycline: A Case Report. *Clin Pediatr (Phila)*. 2015;54(9):904-6.
 116. Davies MG, Kersey PJ. Acute hepatitis and exfoliative dermatitis associated with minocycline. *BMJ*. 1989;298(6686):1523-4.
 117. Edhi AI, Hakim S, Shams C, Bedi D, Amin M, Cappell MS. Clarithromycin-Associated Acute Liver Failure Leading to Fatal, Massive Upper Gastrointestinal Hemorrhage from Profound Coagulopathy: Case Report and Systematic Literature Review. *Case Reports Hepatol*. 2020;2020:2135239.
 118. Simma B, Meister B, Deutsch J, Sperl W, Fend F, Ofner D, et al. Fulminant hepatic failure in a child as a potential adverse effect of trimethoprim-sulphamethoxazole. *Eur J Pediatr*. 1995;154(7):530-3.
 119. Zollner E, Delpont S, Bonnici F. Fatal liver failure due to ketoconazole treatment of a girl with Cushing's syndrome. *J Pediatr Endocrinol Metab*. 2001;14(3):335-8.
 120. Pettit NN, Pisano J, Weber S, Ridgway J. Hepatic Failure in a Patient Receiving Itraconazole for Pulmonary Histoplasmosis-Case Report and Literature Review. *Am J Ther*. 2016;23(5):e1215-21.
 121. Shear NH, Spielberg SP. Anticonvulsant hypersensitivity syndrome. In vitro assessment of risk. *J Clin Invest*. 1988;82(6):1826-32.
 122. Hadzic N, Portmann B, Davies ET, Mowat AP, Mieli-Vergani G. Acute liver failure induced by carbamazepine. *Arch Dis Child*. 1990;65(3):315-7.
 123. Overstreet K, Costanza C, Behling C, Hassanin T, Masliah E. Fatal progressive

- hepatic necrosis associated with lamotrigine treatment: a case report and literature review. *Dig Dis Sci.* 2002;47(9):1921-5.
124. Sajith M, Pawar A, Bafna V, Bartakke S. High-dose methotrexate-induced fulminant hepatic failure and pancytopenia in an acute lymphoblastic leukaemia paediatric patient. *Eur J Hosp Pharm.* 2020;27(3):178-80.
 125. Jonas MM, Eidson MS. Propylthiouracil hepatotoxicity: two pediatric cases and review of the literature. *J Pediatr Gastroenterol Nutr.* 1988;7(5):776-9.
 126. Rosh JR, Dellert SF, Narkewicz M, Birnbaum A, Whittington G. Four cases of severe hepatotoxicity associated with pemoline: possible autoimmune pathogenesis. *Pediatrics.* 1998;101(5):921-3.
 127. Campos Franco J, Martinez Rey C, Perez Becerra E, Gonzalez Quintela A. [Cocaine related fulminant liver failure]. *An Med Interna.* 2002;19(7):365-7.
 128. Andreu V, Mas A, Bruguera M, Salmeron JM, Moreno V, Nogue S, et al. Ecstasy: a common cause of severe acute hepatotoxicity. *J Hepatol.* 1998;29(3):394-7.
 129. Cajanding RJM. MDMA-Associated Liver Toxicity: Pathophysiology, Management, and Current State of Knowledge. *AACN Adv Crit Care.* 2019;30(3):232-48.
 130. Lin NH, Yang HW, Su YJ, Chang CW. Herb induced liver injury after using herbal medicine: A systemic review and case-control study. *Medicine (Baltimore).* 2019;98(13):e14992.
 131. A NW, Hardikar W, Cranswick NE, Somers GR. Probable herbal medication induced fulminant hepatic failure. *J Paediatr Child Health.* 2005;41(9-10):530-1.
 132. Raziq FI. Kava Kava Induced Acute Liver Failure. *Am J Ther.* 2020.
 133. Dinakaran D, Bristow E, Armanious H, Garros D, Yap J, Noga M, et al. Co-ingestion of willow bark tea and acetaminophen associated with fatal infantile fulminant liver failure. *Pediatr Int.* 2017;59(6):743-5.
 134. Lemaigre G, Tebbi Z, Galinsky R, Michowitz S, Abelanet R. [Fulminating hepatitis caused by glue thistle (*Atractylis glummifera*-L.), poisoning. Anatomico-pathological study of 4 cases]. *Nouv Presse Med.* 1975;4(40):2565-8.
 135. Sergi CM. Epigallocatechin-3-Gallate Toxicity in Children: A Potential and Current Toxicological Event in the Differential Diagnosis With Virus-Triggered Fulminant Hepatic Failure. *Front Pharmacol.* 2019;10:1563.
 136. Mattei A, Rucay P, Samuel D, Feray C, Reynes M, Bismuth H. Liver transplantation

- for severe acute liver failure after herbal medicine (*Teucrium polium*) administration. *J Hepatol.* 1995;22(5):597.
137. Bakerink JA, Gospe SM, Jr., Dimand RJ, Eldridge MW. Multiple organ failure after ingestion of pennyroyal oil from herbal tea in two infants. *Pediatrics.* 1996;98(5):944-7.
 138. Sheikh NM, Philen RM, Love LA. Chaparral-associated hepatotoxicity. *Arch Intern Med.* 1997;157(8):913-9.
 139. Neuman MG, Cohen L, Opris M, Nanau RM, Hyunjin J. Hepatotoxicity of Pyrrolizidine Alkaloids. *J Pharm Pharm Sci.* 2015;18(4):825-43.
 140. Crescioli G, Lombardi N, Bettiol A, Marconi E, Risaliti F, Bertoni M, et al. Acute liver injury following *Garcinia cambogia* weight-loss supplementation: case series and literature review. *Intern Emerg Med.* 2018;13(6):857-72.
 141. Hegarty R, Hadzic N, Gissen P, Dhawan A. Inherited metabolic disorders presenting as acute liver failure in newborns and young children: King's College Hospital experience. *Eur J Pediatr.* 2015;174(10):1387-92.
 142. Bitar R, Thwaites R, Davison S, Rajwal S, McClean P. Liver Failure in Early Infancy: Aetiology, Presentation, and Outcome. *J Pediatr Gastroenterol Nutr.* 2017;64(1):70-5.
 143. Alam S, Lal BB. Metabolic Liver Diseases Presenting as Acute Liver Failure in Children. *Indian Pediatr.* 2016;53(8):695-701.
 144. Korman JD, Volenberg I, Balko J, Webster J, Schiodt FV, Squires RH, Jr., et al. Screening for Wilson disease in acute liver failure: a comparison of currently available diagnostic tests. *Hepatology.* 2008;48(4):1167-74.
 145. Kido J, Matsumoto S, Sakamoto R, Mitsubuchi H, Inomata Y, Nakamura K. Recovery of severe acute liver failure without transplantation in patients with Wilson disease. *Pediatr Transplant.* 2018;22(8):e13292.
 146. Morrow G, Tanguay RM. Biochemical and Clinical Aspects of Hereditary Tyrosinemia Type 1. *Adv Exp Med Biol.* 2017;959:9-21.
 147. Mayorandan S, Meyer U, Gokcay G, Segarra NG, de Baulny HO, van Spronsen F, et al. Cross-sectional study of 168 patients with hepatorenal tyrosinaemia and implications for clinical practice. *Orphanet J Rare Dis.* 2014;9:107.
 148. McKiernan PJ, Preece MA, Chakrapani A. Outcome of children with hereditary tyrosinaemia following newborn screening. *Arch Dis Child.* 2015;100(8):738-41.

149. Moreira-Silva H, Maio I, Bandeira A, Gomes-Martins E, Santos-Silva E. Metabolic liver diseases presenting with neonatal cholestasis: at the crossroad between old and new paradigms. *Eur J Pediatr*. 2019;178(4):515-23.
150. Ridel KR, Leslie ND, Gilbert DL. An updated review of the long-term neurological effects of galactosemia. *Pediatr Neurol*. 2005;33(3):153-61.
151. Bigot A, Tchan MC, Thoreau B, Blasco H, Maillot F. Liver involvement in urea cycle disorders: a review of the literature. *J Inherit Metab Dis*. 2017;40(6):757-69.
152. Laemmle A, Gallagher RC, Keogh A, Stricker T, Gautschi M, Nuoffer JM, et al. Frequency and Pathophysiology of Acute Liver Failure in Ornithine Transcarbamylase Deficiency (OTCD). *PLoS One*. 2016;11(4):e0153358.
153. Gallagher RC, Lam C, Wong D, Cederbaum S, Sokol RJ. Significant hepatic involvement in patients with ornithine transcarbamylase deficiency. *J Pediatr*. 2014;164(4):720-5 e6.
154. De Las Heras J, Aldamiz-Echevarria L, Martinez-Chantar ML, Delgado TC. An update on the use of benzoate, phenylacetate and phenylbutyrate ammonia scavengers for interrogating and modifying liver nitrogen metabolism and its implications in urea cycle disorders and liver disease. *Expert Opin Drug Metab Toxicol*. 2017;13(4):439-48.
155. Faghfoury H, Baruteau J, de Baulny HO, Haberle J, Schulze A. Transient fulminant liver failure as an initial presentation in citrullinemia type I. *Mol Genet Metab*. 2011;102(4):413-7.
156. de Groot MJ, Cuppen M, Eling M, Verheijen FW, Rings EH, Reijngoud DJ, et al. Metabolic investigations prevent liver transplantation in two young children with citrullinemia type I. *J Inherit Metab Dis*. 2010;33 Suppl 3:S413-6.
157. Schlune A, Vom Dahl S, Haussinger D, Ensenauer R, Mayatepek E. Hyperargininemia due to arginase I deficiency: the original patients and their natural history, and a review of the literature. *Amino Acids*. 2015;47(9):1751-62.
158. Shekhawat PS, Matern D, Strauss AW. Fetal fatty acid oxidation disorders, their effect on maternal health and neonatal outcome: impact of expanded newborn screening on their diagnosis and management. *Pediatr Res*. 2005;57(5 Pt 2):78R-86R.
159. Alonso EM. Acute liver failure in children: the role of defects in fatty acid oxidation. *Hepatology*. 2005;41(4):696-9.
160. Cao J, Wu H, Li Z. Recent perspectives of pediatric mitochondrial diseases. *Exp Ther Med*. 2018;15(1):13-8.

161. Lee WS, Sokol RJ. Liver disease in mitochondrial disorders. *Semin Liver Dis.* 2007;27(3):259-73.
162. Lee WS, Sokol RJ. Mitochondrial hepatopathies: advances in genetics and pathogenesis. *Hepatology.* 2007;45(6):1555-65.
163. Lee WS, Sokol RJ. Mitochondrial hepatopathies: advances in genetics, therapeutic approaches, and outcomes. *J Pediatr.* 2013;163(4):942-8.
164. Squires RH, Ng V, Romero R, Ekong U, Hardikar W, Emre S, et al. Evaluation of the pediatric patient for liver transplantation: 2014 practice guideline by the American Association for the Study of Liver Diseases, American Society of Transplantation and the North American Society for Pediatric Gastroenterology, Hepatology and Nutrition. *Hepatology.* 2014;60(1):362-98.
165. Parikh S, Karaa A, Goldstein A, Ng YS, Gorman G, Feigenbaum A, et al. Solid organ transplantation in primary mitochondrial disease: Proceed with caution. *Mol Genet Metab.* 2016;118(3):178-84.
166. Feldman AG, Sokol RJ, Hardison RM, Alonso EM, Squires RH, Narkewicz MR, et al. Lactate and Lactate: Pyruvate Ratio in the Diagnosis and Outcomes of Pediatric Acute Liver Failure. *J Pediatr.* 2017;182:217-22 e3.
167. Li ZD, Abuduxikuer K, Zhang J, Yang Y, Qiu YL, Huang Y, et al. NBAS disease: 14 new patients, a recurrent mutation, and genotype-phenotype correlation among 24 Chinese patients. *Hepatol Res.* 2020.
168. Lenz D, McClean P, Kansu A, Bonnen PE, Ranucci G, Thiel C, et al. SCYL1 variants cause a syndrome with low gamma-glutamyl-transferase cholestasis, acute liver failure, and neurodegeneration (CALFAN). *Genet Med.* 2018;20(10):1255-65.
169. Chavany J, Cano A, Roquelaure B, Bourgeois P, Boubnova J, Gaignard P, et al. Mutations in NBAS and SCYL1, genetic causes of recurrent liver failure in children: Three case reports and a literature review. *Arch Pediatr.* 2020;27(3):155-9.
170. Casey JP, McGettigan P, Lynam-Lennon N, McDermott M, Regan R, Conroy J, et al. Identification of a mutation in LARS as a novel cause of infantile hepatopathy. *Mol Genet Metab.* 2012;106(3):351-8.
171. Li H, Byers HM, Diaz-Kuan A, Vos MB, Hall PL, Tortorelli S, et al. Acute liver failure in neonates with undiagnosed hereditary fructose intolerance due to exposure from widely available infant formulas. *Mol Genet Metab.* 2018;123(4):428-32.
172. Rohanizadegan M, Abdo SM, O'Donnell-Luria A, Mihalek I, Chen P, Sanders M, et al. Utility of rapid whole-exome sequencing in the diagnosis of Niemann-Pick disease

- type C presenting with fetal hydrops and acute liver failure. *Cold Spring Harb Mol Case Stud.* 2017;3(6).
173. Patterson J, Hussey HS, Silal S, Goddard L, Setshedi M, Spearman W, et al. Systematic review of the global epidemiology of viral-induced acute liver failure. *BMJ Open.* 2020;10(7):e037473.
 174. Liu Z, Shi O, Zhang T, Jin L, Chen X. Disease burden of viral hepatitis A, B, C and E: A systematic analysis. *J Viral Hepat.* 2020.
 175. Hollinger FB, Khan NC, Oefinger PE, Yawn DH, Schmulen AC, Dreesman GR, et al. Posttransfusion hepatitis type A. *JAMA.* 1983;250(17):2313-7.
 176. Skidmore SJ, Boxall EH, Ala F. A case report of post-transfusion hepatitis A. *J Med Virol.* 1982;10(3):223.
 177. Rezende G, Roque-Afonso AM, Samuel D, Gigou M, Nicand E, Ferre V, et al. Viral and clinical factors associated with the fulminant course of hepatitis A infection. *Hepatology.* 2003;38(3):613-8.
 178. Shah U, Habib Z, Kleinman RE. Liver failure attributable to hepatitis A virus infection in a developing country. *Pediatrics.* 2000;105(2):436-8.
 179. Kayaalp C, Ersan V, Yilmaz S. Acute liver failure in Turkey: a systematic review. *Turk J Gastroenterol.* 2014;25(1):35-40.
 180. Ciocca M, Ramonet M, Cuarterolo M, Lopez S, Cernadas C, Alvarez F. Prognostic factors in paediatric acute liver failure. *Arch Dis Child.* 2008;93(1):48-51.
 181. Talat S, Khan SA, Javed N, Malik MI. Etiology, clinical presentation, and outcome of children with fulminant hepatic failure: Experience from a tertiary center in Pakistan. *Pak J Med Sci.* 2020;36(6):1252-6.
 182. Bravo LC, Gregorio GV, Shafi F, Bock HL, Boudville I, Liu Y, et al. Etiology, incidence and outcomes of acute hepatic failure in 0-18 year old Filipino children. *Southeast Asian J Trop Med Public Health.* 2012;43(3):764-72.
 183. Ciocca M, Moreira-Silva SF, Alegria S, Galoppo MC, Ruttiman R, Porta G, et al. Hepatitis A as an etiologic agent of acute liver failure in Latin America. *Pediatr Infect Dis J.* 2007;26(8):711-5.
 184. Fouad HM, Reyad EM, El-Din AG. Acute hepatitis A is the chief etiology of acute hepatitis in Egyptian children: a single-center study. *Eur J Clin Microbiol Infect Dis.* 2018;37(10):1941-7.

185. Colleti Junior J, Caino FR, Teixeira R, Carvalho WB. Fulminant acute hepatitis in pediatrics in Latin America and the Caribbean. *Rev Assoc Med Bras* (1992). 2019;65(6):914-21.
186. Rajanayagam J, Coman D, Cartwright D, Lewindon PJ. Pediatric acute liver failure: etiology, outcomes, and the role of serial pediatric end-stage liver disease scores. *Pediatr Transplant*. 2013;17(4):362-8.
187. Patra S, Kumar A, Trivedi SS, Puri M, Sarin SK. Maternal and fetal outcomes in pregnant women with acute hepatitis E virus infection. *Ann Intern Med*. 2007;147(1):28-33.
188. Acharya SK, Madan K, Dattagupta S, Panda SK. Viral hepatitis in India. *Natl Med J India*. 2006;19(4):203-17.
189. Gerolami R, Borentain P, Raissouni F, Motte A, Solas C, Colson P. Treatment of severe acute hepatitis E by ribavirin. *Journal of clinical virology : the official publication of the Pan American Society for Clinical Virology*. 2011;52(1):60-2.
190. <https://www.who.int/news-room/fact-sheets/detail/hepatitis-b>. [
191. Chang MH, Lee CY, Chen DS, Hsu HC, Lai MY. Fulminant hepatitis in children in Taiwan: the important role of hepatitis B virus. *J Pediatr*. 1987;111(1):34-9.
192. Ogunbosi B, Smuts H, Eley B, Korsman S, De Lacy R, Hardie DR. Fulminant hepatitis B virus (HBV) infection in an infant following mother-to-child transmission of an e-minus HBV mutant: Time to relook at HBV prophylaxis in South African infants. *S Afr Med J*. 2018;108(5):389-92.
193. Beath SV, Boxall EH, Watson RM, Tarlow MJ, Kelly DA. Fulminant hepatitis B in infants born to anti-HBe hepatitis B carrier mothers. *BMJ*. 1992;304(6835):1169-70.
194. Kumar M, Satapathy S, Monga R, Das K, Hissar S, Pande C, et al. A randomized controlled trial of lamivudine to treat acute hepatitis B. *Hepatology*. 2007;45(1):97-101.
195. Wiegand J, Wedemeyer H, Franke A, Rossler S, Zeuzem S, Teuber G, et al. Treatment of severe, nonfulminant acute hepatitis B with lamivudine vs placebo: a prospective randomized double-blinded multicentre trial. *J Viral Hepat*. 2014;21(10):744-50.
196. Terrault NA, Lok ASF, McMahon BJ, Chang KM, Hwang JP, Jonas MM, et al. Update on prevention, diagnosis, and treatment of chronic hepatitis B: AASLD 2018 hepatitis B guidance. *Hepatology*. 2018;67(4):1560-99.

197. Oketani M, Uto H, Ido A, Tsubouchi H. Management of hepatitis B virus-related acute liver failure. *Clin J Gastroenterol*. 2014;7(1):19-26.
198. Lee HC. Acute liver failure related to hepatitis B virus. *Hepatol Res*. 2008;38 Suppl 1:S9-S13.
199. Aw MM, Dhawan A. Acute liver failure. *Indian J Pediatr*. 2002;69(1):87-91.
200. Kimberlin DW, Lin CY, Jacobs RF, Powell DA, Frenkel LM, Gruber WC, et al. Natural history of neonatal herpes simplex virus infections in the acyclovir era. *Pediatrics*. 2001;108(2):223-9.
201. Schwarz KB, Dell Olio D, Lobritto SJ, Lopez MJ, Rodriguez-Baez N, Yazigi NA, et al. Analysis of viral testing in nonacetaminophen pediatric acute liver failure. *J Pediatr Gastroenterol Nutr*. 2014;59(5):616-23.
202. Verma A, Dhawan A, Zuckerman M, Hadzic N, Baker AJ, Mieli-Vergani G. Neonatal herpes simplex virus infection presenting as acute liver failure: prevalent role of herpes simplex virus type I. *J Pediatr Gastroenterol Nutr*. 2006;42(3):282-6.
203. McGoogan KE, Haafiz AB, Gonzalez Peralta RP. Herpes simplex virus hepatitis in infants: clinical outcomes and correlates of disease severity. *J Pediatr*. 2011;159(4):608-11.
204. Kofteridis DP, Koulentaki M, Valachis A, Christofaki M, Mazokopakis E, Papazoglou G, et al. Epstein Barr virus hepatitis. *Eur J Intern Med*. 2011;22(1):73-6.
205. Sarwari NM, Khoury JD, Hernandez CM. Chronic Epstein Barr virus infection leading to classical Hodgkin lymphoma. *BMC Hematol*. 2016;16:19.
206. Crum NF. Epstein Barr virus hepatitis: case series and review. *South Med J*. 2006;99(5):544-7.
207. Lawee D. Mild infectious mononucleosis presenting with transient mixed liver disease: case report with a literature review. *Can Fam Physician*. 2007;53(8):1314-6.
208. Salva I, Silva IV, Cunha F. Epstein-Barr virus-associated cholestatic hepatitis. *BMJ Case Rep*. 2013;2013.
209. Dorman JM, Glick TH, Shannon DC, Galdabini J, Walker WA. Complications of Infectious Mononucleosis: A Fatal Case in a 2-Year-Old Child. *American Journal of Diseases of Children*. 1974;128(2):239-43.
210. Jain S, Sherlock S. Infectious mononucleosis with jaundice, anaemia, and encephalopathy. *Br Med J*. 1975;3(5976):138-9.

211. Hart GK, Thompson WR, Schneider J, Davis NJ, Oh TE. Fulminant hepatic failure and fatal encephalopathy associated with Epstein-Barr virus infection. *Med J Aust.* 1984;141(2):112-3.
212. Shaw NJ, Evans JH. Liver failure and Epstein-Barr virus infection. *Arch Dis Child.* 1988;63(4):432-3.
213. Iijima T, Sumazaki R, Mori N, Oka K, Nagai Y, Shibazaki M, et al. A pathological and immunohistological case report of fatal infectious mononucleosis, Epstein-Barr virus infection, demonstrated by in situ and Southern blot hybridization. *Virchows Arch A Pathol Anat Histopathol.* 1992;421(1):73-8.
214. Tazawa Y, Nishinomiya F, Noguchi H, Takada G, Tsuchiya S, Sumazaki R, et al. A case of fatal infectious mononucleosis presenting with fulminant hepatic failure associated with an extensive CD8-positive lymphocyte infiltration in the liver. *Hum Pathol.* 1993;24(10):1135-9.
215. Feranchak AP, Tyson RW, Narkewicz MR, Karrer FM, Sokol RJ. Fulminant Epstein-Barr viral hepatitis: orthotopic liver transplantation and review of the literature. *Liver Transpl Surg.* 1998;4(6):469-76.
216. Nakazawa A, Nakano N, Fukuda A, Sakamoto S, Imadome K, Kudo T, et al. Use of serial assessment of disease severity and liver biopsy for indication for liver transplantation in pediatric Epstein-Barr virus-induced fulminant hepatic failure. *Liver Transpl.* 2015;21(3):362-8.
217. Nordenstrom A, Hellerud C, Lindstedt S, Alm J, Fischler B, Nemeth A, et al. Acute liver failure in a child with Epstein-Barr virus infection and undiagnosed glycerol kinase deficiency, mimicking hemophagocytic lymphohistiocytosis. *J Pediatr Gastroenterol Nutr.* 2008;47(1):98-101.
218. Palanduz A, Yildirmak Y, Telhan L, Arapoglu M, Urganci N, Tufekci S, et al. Fulminant hepatic failure and autoimmune hemolytic anemia associated with Epstein-Barr virus infection. *J Infect.* 2002;45(2):96-8.
219. Oberdorfer P, Kongthavonsakul K, Towiwat T, Klangkalya N. Unusual manifestations of Epstein-Barr virus infection in an 8-month-old male infant. *BMJ Case Rep.* 2012;2012.
220. Baumgarten E, Herbst H, Schmitt M, Seeger KH, Schulte-Overberg U, Henze G. Life-threatening infectious mononucleosis: is it correlated with virus-induced T cell proliferation? *Clin Infect Dis.* 1994;19(1):152-6.
221. Sullivan JL. Epstein-Barr virus and the X-linked lymphoproliferative syndrome. *Adv Pediatr.* 1983;30:365-99.

222. Suh N, Liapis H, Misdraji J, Brunt EM, Wang HL. Epstein-Barr virus hepatitis: diagnostic value of in situ hybridization, polymerase chain reaction, and immunohistochemistry on liver biopsy from immunocompetent patients. *Am J Surg Pathol.* 2007;31(9):1403-9.
223. Ozkan TB, Mistik R, Dikici B, Nazlioglu HO. Antiviral therapy in neonatal cholestatic cytomegalovirus hepatitis. *BMC Gastroenterol.* 2007;7:9.
224. Gray GC, McCarthy T, Lebeck MG, Schnurr DP, Russell KL, Kajon AE, et al. Genotype prevalence and risk factors for severe clinical adenovirus infection, United States 2004-2006. *Clin Infect Dis.* 2007;45(9):1120-31.
225. Wang WH, Wang HL. Fulminant adenovirus hepatitis following bone marrow transplantation. A case report and brief review of the literature. *Arch Pathol Lab Med.* 2003;127(5):e246-8.
226. McKillop SJ, Belletrutti MJ, Lee BE, Yap JY, Noga ML, Desai SJ, et al. Adenovirus necrotizing hepatitis complicating atypical teratoid rhabdoid tumor. *Pediatr Int.* 2015;57(5):974-7.
227. Ronan BA, Agrwal N, Carey EJ, De Petris G, Kusne S, Seville MT, et al. Fulminant hepatitis due to human adenovirus. *Infection.* 2014;42(1):105-11.
228. Neofytos D, Ojha A, Mookerjee B, Wagner J, Filicko J, Ferber A, et al. Treatment of adenovirus disease in stem cell transplant recipients with cidofovir. *Biol Blood Marrow Transplant.* 2007;13(1):74-81.
229. Cantor A, Miller J, Zachariah P, DaSilva B, Margolis K, Martinez M. Acute hepatitis is a prominent presentation of the multisystem inflammatory syndrome in children: a single-center report. *Hepatology.* 2020.
230. Lagana SM, De Michele S, Lee MJ, Emond JC, Griesemer AD, Tulin-Silver SA, et al. COVID-19 Associated Hepatitis Complicating Recent Living Donor Liver Transplantation. *Arch Pathol Lab Med.* 2020.
231. Dhawan A. Etiology and prognosis of acute liver failure in children. *Liver Transpl.* 2008;14 Suppl 2:S80-4.
232. McDonald GB, Hinds MS, Fisher LD, Schoch HG, Wolford JL, Banaji M, et al. Veno-occlusive disease of the liver and multiorgan failure after bone marrow transplantation: a cohort study of 355 patients. *Ann Intern Med.* 1993;118(4):255-67.
233. Senzolo M, Germani G, Cholongitas E, Burra P, Burroughs AK. Veno occlusive disease: update on clinical management. *World J Gastroenterol.* 2007;13(29):3918-24.

234. Kathuria R, Srivastava A, Yachha SK, Poddar U, Baijal SS. Budd-Chiari syndrome in children: clinical features, percutaneous radiological intervention, and outcome. *Eur J Gastroenterol Hepatol*. 2014;26(9):1030-8.
235. Mancuso A. Timing of Transjugular Intrahepatic Portosystemic Shunt for Budd-Chiari Syndrome: An Italian Hepatologist's Perspective. *J Transl Int Med*. 2017;5(4):194-9.
236. Gu RL, Xiang M, Suo J, Yuan J. Acute lymphoblastic leukemia in an adolescent presenting with acute hepatic failure: A case report. *Mol Clin Oncol*. 2019;11(2):135-8.
237. Litten JB, Rodriguez MM, Maniaci V. Acute lymphoblastic leukemia presenting in fulminant hepatic failure. *Pediatr Blood Cancer*. 2006;47(6):842-5.
238. van Marcke C, Coulier B, Gielen I, Maldague P. Acute liver failure secondary to metastatic liver infiltration: case report and review of the literature. *Acta Gastroenterol Belg*. 2013;76(4):436-8.

Figure 1. The clinical trajectory of a child with acute liver failure is dynamic. Liver transplantation interrupts the natural history of acute liver failure.

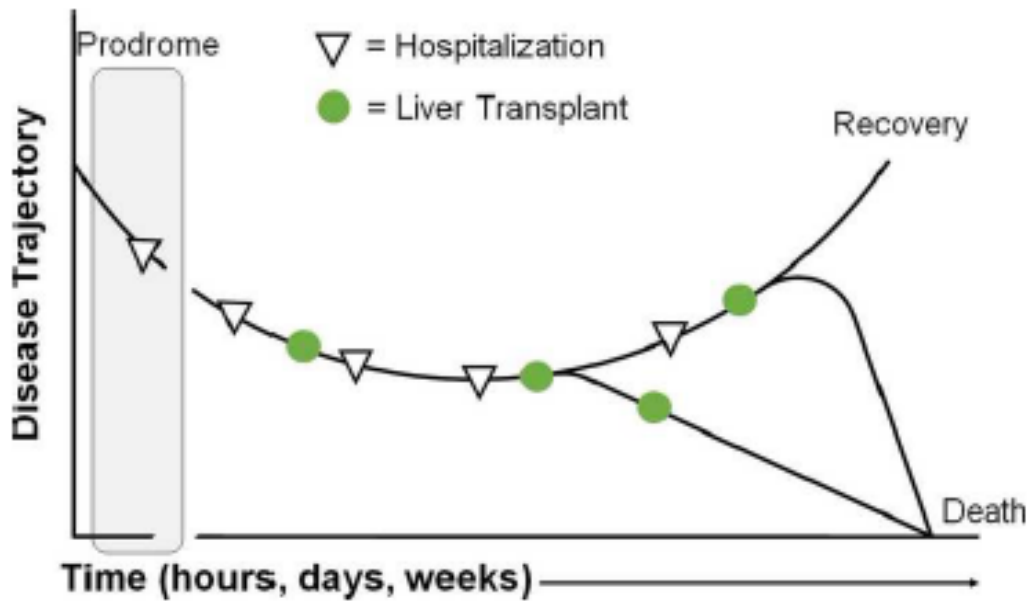


Figure 2. A general management algorithm for patients meeting PALF study entry criteria

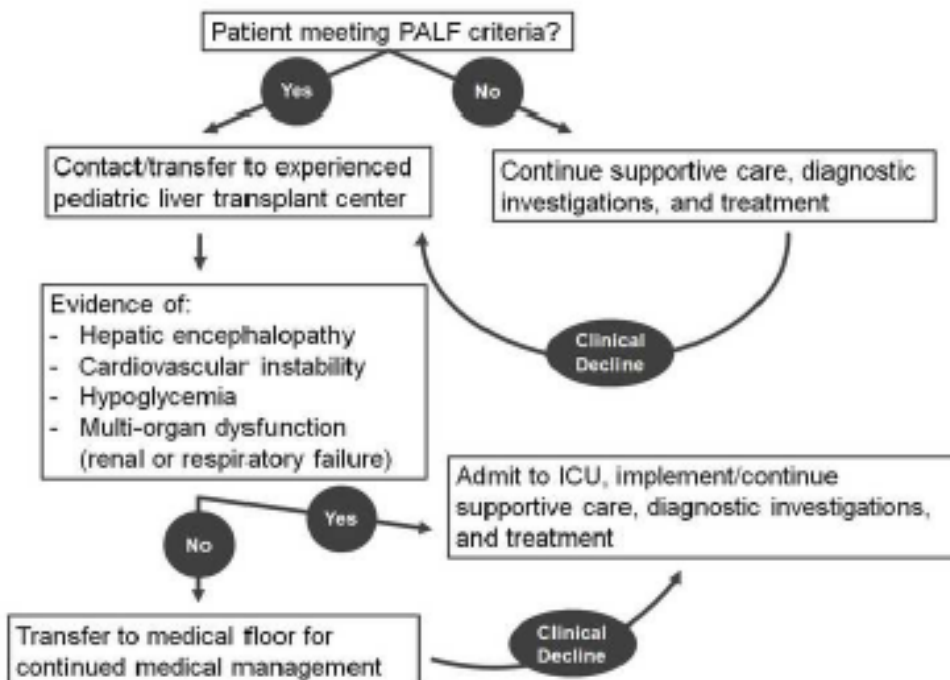


Figure 3. Etiology of acute liver failure in Children. **A.** Etiology for 1144 children from the Pediatric Acute Liver Failure Study Group (PALFSG) 1999 – 2014. **B.** Final diagnosis by age (Note: figure B includes information on only 985 participants) Data modified from ref (94)

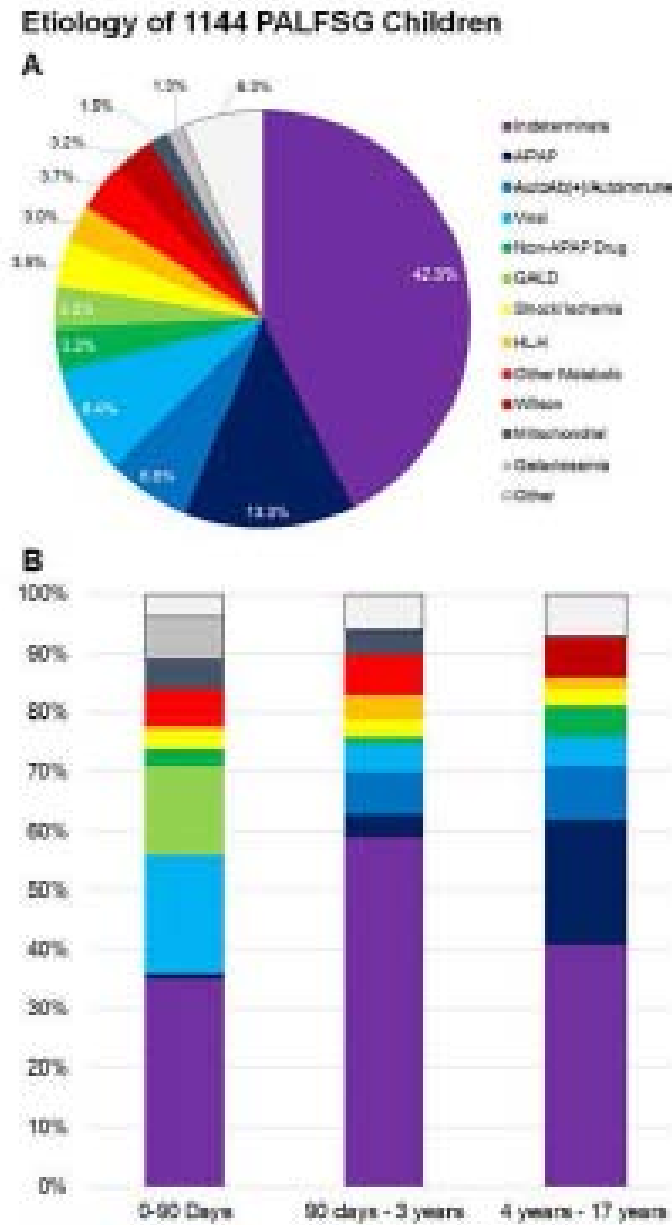


Table 1: PALFSG study entry criteria – all 3 components required:

Acute onset of liver disease without evidence of chronic liver disease
Biochemical evidence of severe liver injury
Coagulopathy not corrected by vitamin K <ul style="list-style-type: none"> • Prothrombin time (PT) \geq 15 seconds or INR \geq 1.5 <i>with</i> evidence of hepatic encephalopathy or • PT \geq 20 seconds or INR $>$ 2 <i>with or without</i> encephalopathy
PALFSG: pediatric acute liver failure study group; INR: international normalized ratio

Table 2: Important historical aspects of common etiologies of PALF

Etiology	Pertinent historical information
Infectious	Recent travel Known sick contacts
Toxic	Prescribed and over-the-counter medications Herbal supplements Illicit drug use Consumption of wild mushrooms Exposure to household or industrial chemicals
Autoimmune	Family history of autoimmune disease
Metabolic	Preexisting developmental delay Family history of liver disease Consanguinity Family history of recurrent late miscarriage or early infant death Episodes of altered mental status or confusion

PALFSG: pediatric acute liver failure study group

Table 3: Physical exam findings suggestive of preexisting or chronic liver disease

Organ System	Physical exam findings
General or Constitutional	Growth failure Dysmorphic features
Abdominal	Hepatosplenomegaly suggestive of portal hypertension Ascites
Musculoskeletal	Digital clubbing Rachitic rosary
Skin	Xanthomas Abdominal varices or spider angiomas Peripheral edema

Table 4. Clinical assessments, laboratory testing, and diagnostic evaluation in PALF

Initial Clinical Testing Independent of Age	Age-based Diagnostic Testing		Recommended age of diagnostic testing		
Live	PT/INR	Suspected Etiology	Recommended tests	<3 mo	3 mo to 18 y
Function:	Bilirubin (total and fractionated)	Systemic herpes infection	Herpes blood PCR	x	x
	Total protein and albumin	Urea cycle; other metabolic defects	Serum amino acid profile	x	x
	Ammonia	GA LD screen	Ferritin	x	
	Glucose	Mitochondrial screen	Lactate, pyruvate	x	x
Multisystem	BMP + calcium, magnesium, phosphorus	FAO defects	Plasma acylcarnitine profile	x	x
Assessment:	CBC + platelets and differential	Tyrosinemia	Urine succinylacetone	x	
	Amylase	Systemic enterovirus	Enterovirus blood	x	x

				and lipase		infection ^{&}	PCR			
				Blood gases (mixed, venous, or arterial)		Acetami nophen toxicity	Acetamin ophen level		x	
Live r Inju ry:				ALT		Hep atiti s A	Hepatitis A virus IgM		x	
				AST		Hep atiti s B	Hepatitis B surface antigen		x	
				GGT		EB V infe ctio n	EBV VCA IgM or PCR		x	
				ferritin		Autoimm une Disease	Antinucle ar antibody		x	
							Anti- smooth muscle ab		x	
							Liver kidney microsom al ab		x	
							IgG		x	
						Wilson disease ^{\$}	Cerulopla smin		x	
							24-hour urine copper		x	
						DILI/HD S Exposure	Dru g hist ory		x x	
				Q30 minu tes		Neurologic al checks	Galactosemia and tyrosinemia	Confirm newborn screen results		x

Q 60 minutes	Neurological checks	vital signs		Hepatitis B in newborn	Confirm maternal hepatitis B serology	x	
Q 2 hours	Neurological checks			Viral infection	Viral testing for adenovirus, enterovirus, HHV-6, parvovirus, influenza	x	x
Q 4 hours		vital signs	dextrostik**				
Q 6 hours	vital signs		BMP, magnesium, ammonia, CBC***	HLH	Soluble IL2R, ferritin, triglyceride level	x	x
Q 8 hours	dextrostik		dextrostik*, BMP, magnesium, ammonia, CBC	Vascular/Anatomical Abnormality	Abdominal ultrasound with Doppler	x	x
Q 12 hours	dextrostik, BMP, magnesium, ammonia, CBC, Liver function and injury	Liver function and injury	Liver function and injury	Infection	Blood culture	x	x

Ab: antibody; ALT: alanine aminotransferase; APAP: acetaminophen; AST: aspartate aminotransferase; BMP: basic metabolic panel; CBC: complete blood count; DILI: drug induced liver injury; EBV: Epstein-Barr virus.

FAO: fatty acid oxidation defects; GALD: gestational alloimmune liver disease; GGT:

gamma glutamyl transferase; HDS: herbal dietary supplement; HE: hepatic encephalopathy; HHV-6: human herpes virus-6; HLH: hemophagocytic lymphohistiocytosis; IgG: immunoglobulin G; IL2r: interleukin-2 receptor; INR: International normalized ratio; PCR: polymerase chain reaction; VCA: viral capsule antigen

*No

hypoglycemia
in the last 48
hours

**When there are acute changes in mental status. When hypoglycemia is identified, obtain serum blood sugar to ensure glucose is greater than 100 mg/dl and is stable within the normal range

***When
severe ascites
and/or
hypoalbumine
mia

& unlikely
needed > 3 y

\$ unlikely
needed < 1 y

ACCEPTED

Table 5. Diagnostic and management strategies of common complications in PALF

Complication	Diagnosis	Management
Fluids and Electrolytes		<ul style="list-style-type: none"> • Maintain glucose levels between 90 to 120 mg/dL
Hyper/hypoglycemia	Regular blood monitoring	<ul style="list-style-type: none"> • Both hyper- and hypoglycemia are associated with complications (22) • Protracted and profound hypoglycemia may be suggestive of an underlying metabolic defect and should prompt additional testing that includes ammonia, lactate, serum amino acids • Glucose infusion rate may need to be 10-15 mg/kg/min and IV glucose concentrations may need to be above 20% Dextrose to maintain proper glucose levels (23)
Hyper/hyponatremia	Routine blood monitoring	<ul style="list-style-type: none"> • Maintain sodium requirements of 2-3 mEq/kg/d • Treat hyponatremia when patient is symptomatic or Na <120 mEq/L or fluid restriction not possible • Maintaining Na between 145 to 155 mmol/L may improve intracranial hypertension, but only temporarily and sustained hypernatremia should be avoided (24)
Hypophosphatemia	Routine blood monitoring	<ul style="list-style-type: none"> • Hypophosphatemia is common and should be treated to keep serum level over 3 mg/dL (25)
Ascites	Physical exam, imaging (US, CT)	<ul style="list-style-type: none"> • Often precipitates by ↓ albumin, excessive fluid administration, and infection • Treat precipitating factor if identified • Fluid restriction • Diuretics reserved for refractory cases or complications of fluid overload (respiratory compromise etc.) <ul style="list-style-type: none"> ○ Aggressive diuresis may precipitate HRS
HE and hyperammonemia	Physical exam, EEG, CT*	<p>Clinical management</p> <ul style="list-style-type: none"> • Elevate head to 30° • Dim and quiet room with no sudden noises or unnecessary chatter • Place pads on bed rails to prevent injury from sudden movements or combative behavior

			<ul style="list-style-type: none"> • Minimize tracheal suctioning if intubated
		Medical management	<ul style="list-style-type: none"> • Consider reduced protein intake to 1 mg/kg • Lactulose 0.5cc/kg/dose up to 30cc/dose; adjust to produce 2-4 stools per day; acid intraluminal environment favors conversion of ammonia (NH₃) produced by gut microbiome to ammonium (NH₄⁺) thus decreasing intestinal absorption (26) • Rifaximin to alter intestinal microbiome and decrease NH₃ production; efficacy is comparable to lactulose in adults (27), but vary sparse data in children • There are conflicting studies on the efficacy of L-ornithine-L-aspartate in adults (28-30), but has not been studied satisfactorily in children. • Consideration of empiric antibiotics (31) and extracorporeal support devices (32)
		Exacerbating factors include: sepsis, shock or hypotension, GI bleeding, renal failure, electrolyte imbalance (33)	
Cerebral edema	<ul style="list-style-type: none"> •CT: effacement of Sylvian fissures, sulci, and basal cisterns, loss of grey and white matter differentiation •Direct monitoring via intracranial pressure transducer (ICP 'bolt') •Ultrasonography of optic 	ICP monitoring considered in:	<ul style="list-style-type: none"> • Patients with stage III or IV coma • Require mechanical ventilation • EEG with slowing • ↑↑ ammonia • CT scan with features of edema • Hemorrhage is most feared complication of invasive bolt placement (35) • Noninvasive assessment such as ONSD, NIRS, TMD, and TCD deserve future study (36)
		Overall goals: (37)	<ul style="list-style-type: none"> • Clinical stability or improvement • ICP pressure <20 mmHg • Maintain cerebral perfusion pressure >50 mmHg for children <4 years, >55 mmHg for children 4-10 years, and >60 mmHg for children over 10 years

	nerve sheath diameter (ONSD) (34)**	<p>Specific Therapies:</p> <ul style="list-style-type: none"> • Hypothermia (core body temperature 32-33°) was reported to improve outcome in small case series, but was not found to confer benefit in two randomized trials (38, 39) • Indomethacin has been studied for its anti-inflammatory properties (40), but concerns regarding bleeding risk and renal toxicity has likely precluded its acceptance as a reasonable treatment option • Forced hyperventilation to reduce pCO₂ below 34 mmHg. Brief (e.g., 20 minutes) bursts of forced hyperventilation may be most effective as extended hypocapnia may place the patient at risk for hypoxia (41) • Hyperosmolar therapy (42) <ul style="list-style-type: none"> ○ Mannitol 0.5 to 1.0 g/kg. Can be given via a peripheral vein. Can produce a brisk diuresis, so careful monitoring of cardiovascular status is needed. No additional benefit is serum osmolality > 320 mOsm/kg ○ Hypertonic saline (2% to 23.4%) to maintain serum sodium between 145-155 meq/L. Transtentorial herniation has been reversed with 23.4% may extend the window for liver transplantation (43)
Coagulopathy	<p>↑↑ INR</p> <p>↓ Factor V and VII</p> <p>↓ Fibrinogen</p>	<ul style="list-style-type: none"> • Vitamin K repletion – consider intravenous route to assure administration • Fresh frozen plasma (FFP) and or platelets for active bleeding or an invasive procedure • Avoid FFP and platelets to just correct the INR or improve platelet count in the absence of bleeding as both are associated with transfusion related lung injury and fluid overload (44) • Cryoprecipitate for low fibrinogen levels (e.g., <100 mg/dL) • Recombinant factor VII has been used to correct the INR prior to placement of an intracranial monitor. It is very expensive and there is a risk of thrombosis (45) • As pro- and anti-coagulant proteins are both depressed, thromboelastography (TEG) is often normal, although hyper- and hypo-coagulable states may occur (46)
Kidney injury	<p>RIFLE criteria (47)</p> <p>↓ Creatinine</p>	<ul style="list-style-type: none"> • Continuous renal replacement therapy (CRRT) (48)

	clearance ↓ Urine output	
Infections	Positive culture	If clinical or biochemical changes occur, blood cultures and tracheal cultures, if intubated, should be obtained and broad-spectrum antibiotics started until cultures return negative
Cardiovascular dysfunction	Vital sign instability <ul style="list-style-type: none"> • Hypotension • Tachycardia • Abnormal EKG/echo 	<ul style="list-style-type: none"> • Consider vasopressor support to maintain age-appropriate blood pressure <ul style="list-style-type: none"> ○ NE is agent of choice in adults ○ Low dose vasopressin (1 – 2 units/hour) should be considered if NE requirements escalate (49)

CT: computerized tomography; EEG: electroencephalogram; EKG: electrocardiography; HE: hepatic encephalopathy; HRS: hepatorenal syndrome; ICP: intracranial pressure; INR: international normalized ratio; NIRS: near-infrared spectroscopy; NE: norepinephrine; RIFLE: Risk, Injury, Failure, Loss, End-stage; TCD: transcranial Doppler; TMD: tympanic membrane displacement; US: ultrasound; WBC: white blood cell

* avoid contrast if evidence of renal injury

**greater than 6.1 mm is a potentially novel approach studied in pediatric traumatic brain injury, but not in PALF

Table 6: Assessment of Encephalopathy

For Young Children (age < 4 years): Modified from (13)				
Grade	Mental status	Reflexes	Neurological signs	EEG Changes
Early (Stage 1 and 2)	Inconsolable crying, sleep reversal, inattention to task	Unreliable/normal or hyperreflexic	Difficult to test. Responses may be delayed, and attention span shortened	Normal or mild slowing
Mid (Stage 3)	Somnolence, stupor, combativeness	Unreliable – can be decreased, absent, or increased	Difficult to test. Progressive decrease in response to external stimuli	Mild or moderate background abnormality with slowing
Late (Stage 4)	Comatose, arouses with painful stimuli or no response	Unreliable – can be decreased, absent, or increased	Decerebrate or decorticate	Severe attenuation or slowing
For Children (age > 4 years): modified from (51, 52)				
Stage	Mood and mental Status	Reflexes	Neurological signs	EEG Changes
Stage 1, prodromal	Mood swing: euphoria/depression; mild confusion; slowness of mentation and affect; untidiness; slurred speech; disordered sleep	Normal or hyperreflexic	Tremor, apraxia, impaired handwriting	Normal or diffuse slowing
Stage 2	Accentuation of Stage 1; lethargy; moderate confusion; inappropriate behavior; inability to maintain sphincter control	Hyperreflexic	Ataxia, dysarthria	Abnormal, generalized slowing
Stage 3, stupor	Marked confusion; sleepy but arousable; incoherent speech	Hyperreflexic	Rigidity	Abnormal, generalized slowing
Stage 4, coma	May or may not respond to painful stimuli	Usually absent	Decerebrate or decorticate	Abnormal, very slow

EEG: Electroencephalography

Table 7. Stages of APAP Toxicity

Stage	Time following ingestion	Clinical signs and symptoms
I	<24 hours	<ul style="list-style-type: none"> • Non-specific features such as nausea, vomiting, abdominal pain • Lab test often normal, or near normal
II	24 – 72 hours	<ul style="list-style-type: none"> • RUQ abdominal pain • LFT and INR elevations
III	73 – 96 hours	<ul style="list-style-type: none"> • HE, AKI, MOF • Severe liver injury with markedly increased LFTs <ul style="list-style-type: none"> ○ Bilirubin may be elevated, but often to lesser degree than expected ○ Rising bilirubin is ominous sign • Metabolic acidosis with increased anion gap • Worsening coagulopathy • Mortality is highest
IV	>96 hours	<ul style="list-style-type: none"> • Recovery stage • Clinical and biochemical symptoms improve

AKI: acute kidney injury; APAP: acetaminophen; HE: hepatic encephalopathy; INR: international normalized ratio; LFT: liver function tests; MOF: multi-organ failure

Table 8 Non-Acetaminophen Drug Induced Liver Injury

Classification		Interval between exposure and manifestations	Clinical Features
Analgesic	Halothane (107)	1-30 days	Fever, anorexia, myalgia, rash, jaundice
	Sevoflurane (108)	2-7 days	Jaundice, abdominal pain
Antimicrobials	Isoniazid (109, 110)	0-14 months	fatigue, anorexia, malaise, then jaundice
	Rifampin (111)	weeks	Jaundice, severe hepatitis
	Pyrazinamide (112, 113)	4-8 weeks	fatigue, anorexia, malaise, then jaundice
	Amoxicillin/clavulanic acid (114)	days - 2months	DRESS, severe hepatitis, cholestasis
	Tetracycline (115)	4-6 days into therapy	Nausea, vomiting, abdominal pain, mild jaundice
	Minocycline (116)	days - 2months	DRESS, severe hepatitis
		Months to a year	Autoimmune hepatitis
	Macrolide (117)	1-3 weeks	Nausea, abdominal pain, jaundice, fever
	Sulfonamide (118)	days - 1 month	Fever, rash, eosinophilia, jaundice
	Ketoconazole (119)	1-6 months	Acute hepatitis
Itraconazole (120)	1-6 months	Fatigue, jaundice, severe hepatitis	
Antiepileptic	Phenytoin (121)	2-8 weeks	Hepatitis, cholestasis, atypical lymphocytes, lymphadenopathy
	Carbamazepine (122)	1-8 weeks	DRESS, severe hepatitis
	Lamotrigine (123)	1-8 weeks	DRESS, mild to moderate hepatitis, cholestasis

	Felbamate (58)	1-6 months	Severe hepatitis, cholestasis
	Valproate (106)	Months to years	hyperammonemia
		1-6 months	Jaundice, severe hepatitis
Other	Methotrexate (124)	2-7 days	Drowsiness, altered mental status
	Propylthiouracil (125)	1-7 months	Jaundice, hepatomegaly
	Pemoline (126)	1-9 months	Jaundice, fatigue, fever, abdominal pain
Recreational drugs	Cocaine (127)	Hours to a few days	Acute hepatic necrosis
	MDMA (128, 129)	Hours to a few days	Acute severe hepatitis, jaundice

* DRESS: Drug Rash with Eosinophilia and Systemic Symptoms; MDMA: 3,4-methylenedioxy-methamphetamine